



12-2017

Emergency Department Repair of Blunt Right Atrial Rupture Utilizing Cardiopulmonary Bypass

Samuel P. Carmichael

University of Kentucky, SAM.CARMICHAEL@uky.edu

Michael C. Bounds

University of Kentucky, michael.bounds@uky.edu


Alexis E. Shafii

University of Kentucky, alexis.shafii@uky.edu

Phillip K. Chang

University of Kentucky, pkchan0@email.uky.edu

Follow this and additional works at: https://uknowledge.uky.edu/internalmedicine_facpub

 Part of the [Cardiology Commons](#), [Critical Care Commons](#), [Emergency Medicine Commons](#), [Surgery Commons](#), and the [Trauma Commons](#)

[Right click to open a feedback form in a new tab to let us know how this document benefits you.](#)

Repository Citation

Carmichael, Samuel P.; Bounds, Michael C.; Shafii, Alexis E.; and Chang, Phillip K., "Emergency Department Repair of Blunt Right Atrial Rupture Utilizing Cardiopulmonary Bypass" (2017). *Internal Medicine Faculty Publications*. 124.

https://uknowledge.uky.edu/internalmedicine_facpub/124

This Article is brought to you for free and open access by the Internal Medicine at UKnowledge. It has been accepted for inclusion in Internal Medicine Faculty Publications by an authorized administrator of UKnowledge. For more information, please contact UKnowledge@lsv.uky.edu.

Emergency Department Repair of Blunt Right Atrial Rupture Utilizing Cardiopulmonary Bypass

Digital Object Identifier (DOI)

<https://doi.org/10.1016/j.tcr.2017.09.004>

Notes/Citation Information


Published in *Trauma Case Reports*, v. 12, p. 1-3.

© 2018 Elsevier Ltd.

This is an open access article under the CC BY-NC-ND license (<http://creativecommons.org/licenses/by-nc-nd/4.0/>).

Contents lists available at [ScienceDirect](http://www.sciencedirect.com)

Trauma Case Reports

journal homepage: www.elsevier.com/locate/tcr

Case report

Emergency department repair of blunt right atrial rupture utilizing cardiopulmonary bypass[☆]

Samuel P. Carmichael^{a,*}, Michael C. Bounds^a, Alexis E. Shafiq^b, Phillip K. Chang^c

^a General Surgery Residency Program, University of Kentucky College of Medicine, Lexington, KY, United States

^b Division of Cardiothoracic Surgery, University of Kentucky College of Medicine, Lexington, KY, United States

^c Division of General Surgery – Section of Trauma and Critical Care, University of Kentucky College of Medicine, Lexington, KY, United States

ARTICLE INFO

Keywords:

Blunt cardiac injury
Cardiopulmonary bypass
Atrial rupture
Emergency medicine

ABSTRACT

Blunt cardiac injury (BCI) with free wall rupture carries a high risk of pre-hospital death. Cardiopulmonary bypass (CPB) has been utilized as a bridge to repair of cardiac lesions in select patients. We present an interesting case of emergency department repair of right atrial rupture with cardiopulmonary bypass.

Introduction

Blunt cardiac injury (BCI) ranges in presentation from myocardial bruising to chamber rupture. The frequency of BCI is 20% across this spectrum in motor vehicle collision fatalities [1,2]. In clinical and autopsy series, the incidence of right atrial free wall rupture among BCI varies from 8 to 65% and 10–15%, respectively [1]. However, BCI with rupture represents < 2% of hospital admissions, underscoring the high risk of death at the scene [3]. Though the mortality of patients arriving alive to the hospital is reported up to 89%, increased survival is associated with rupture of a low-pressure chamber or coronary vein [1,4].

Cardiopulmonary bypass (CPB) is uncommonly utilized in the setting of trauma, though successful outcomes have been described in the adult and pediatric literature with possible initiation in the emergency department [5,6]. CPB for surgical repair of cardiac injuries is historically reported in approximately 10% of cases and is employed based on surgeon judgment and the complexity of the lesion [5,7]. We present an interesting case of emergency department initiation of CPB with subsequent repair of right atrial rupture.

Case

A 20-year-old female presented to the emergency department as a transfer patient from an outside facility with a diagnosis of pericardial effusion following a motor-vehicle collision. Upon initial evaluation, she was awake with stable vital signs, though drowsy and combative. A pericardial effusion was visualized on FAST (focused assessment with sonography in trauma) ultrasound. No signs of tension pneumothorax or tamponade were observed. Upon intubation the patient became hemodynamically unstable, and the decision was made to enter the chest via left thoracotomy. There was an immediate rush of blood following incision of the pericardium. Cardiac massage was initiated. Because of poor visualization, the incision was extended across the sternum to include right thoracotomy (clamshell). The source of bleeding was identified as a right atrial rupture at the atrioventricular groove just medial to the auricle. Temporary control was achieved by manual compression over the injury, and cardiac massage was continued. Due to the

[☆] Note: There was no external support provided for this report.

* Corresponding author at: University of Kentucky, 800 Rose Street, C-234, Lexington, KY 40536-0298, United States.

E-mail address: sam.carmichael@uky.edu (S.P. Carmichael).

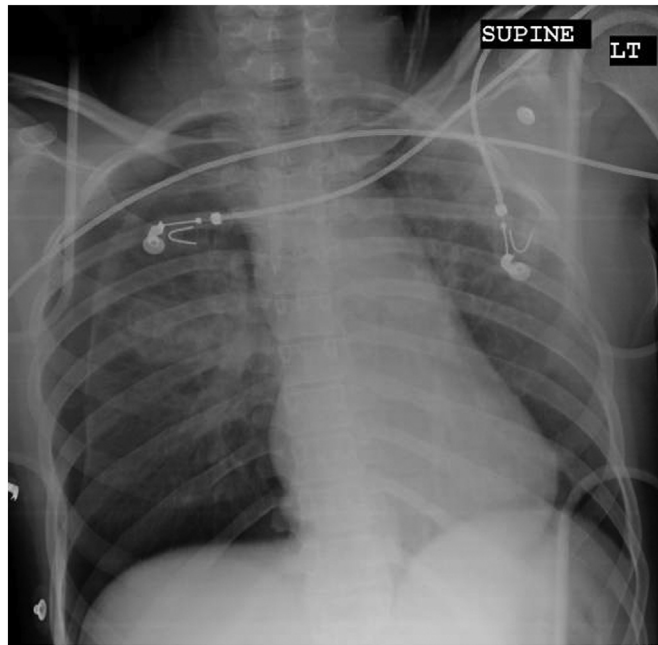


Fig. 1. Emergency department chest x-ray revealing right pneumothorax, apical opacities, and loss of aorticopulmonary window.

size and location of the atrial injury, use of CPB was required. A heart-lung machine was transported into the trauma bay. The patient was systemically heparinized, and cannulas were placed in the left femoral vein and ascending aorta. After initiation of CPB, the patient was systemically cooled to 24 °C. With the heart fibrillating, the right atrial tear was repaired with a running 4–0 prolene suture with careful attention to avoid the course of the right coronary artery. Following rewarming, the patient was defibrillated and weaned from cardiopulmonary bypass without difficulty.

Discussion

BCI with rupture approaches universal fatality. For patients who survive to hospital presentation, identification may remain a diagnostic dilemma as few clinical signs or symptoms are specific within the spectrum of injury [1]. Chest pain, head injury, and rib fractures are most commonly associated [1]. Volumes of hemopericardium < 200 mL may remain asymptomatic and absent of the classic findings of tamponade [1]. In the present case, suspicion for cardiac injury was raised by pericardial effusion identified on emergency department ultrasound with associated loss of aorticopulmonary window and pulmonary contusions identified on chest radiography (Fig. 1). Given the absence of hemodynamic instability and tamponade physiology, the decision was made to perform endotracheal intubation for inability to maintain airway protection. Upon induction, worsening bradycardia with hypotension was noted and the decision was made to enter the left chest in the trauma bay, revealing tense pericardium.

Surgical approaches for exposure of possible cardiac and great vessel injury include left thoracotomy, right thoracotomy (alone or extension clamshell), and median sternotomy [8]. Onan et al. suggest that surgical incision should be made on the basis of mechanism and clinical suspicion, advocating lateral thoracotomy with possible extension in the unstable patient [9]. In that study, median sternotomy was performed in approximately 10% of cases which were clinically stable prior to surgery with likely diagnosis of isolated cardiac injury [9]. However, median sternotomy has also been cited as the incision of choice in BCI with rupture for several-fold rationale: best cardiac exposure, extension of prior subxiphoid incision (prior percutaneous drainage), possible extension for intraabdominal exploration/procedures, and exposure for CPB in complex cases [3]. Emergency department pericardiocentesis for tamponade is an alternative bridge to the operating room and is well reported in the literature [3,8]. In this case, pericardial entry revealed brisk bleeding, and lateral thoracotomy was immediately extended to clamshell for improved exposure.

The right atrial appendage is the most common site of free wall rupture, owing to its thin wall and anterior position [1]. Two mechanisms are most commonly implicated: deceleration and torsion about a fixed point (i.e., tear at the right atrial-caval junction) or sudden compression (hydraulic effect) of the right atrium via chest wall or spinal concussion [1]. The present case demonstrated a large laceration of the right atrium at the level of the right atrial appendage along the atrioventricular groove. Given the location, this injury was most consistent with the latter mechanism of sudden compression in the context of high-speed motor vehicle collision impact. Due to the complexity and location of the injury, CPB was necessary for repair.

The use of CPB in the setting of trauma has been described since the 1990s. However, current emergency department initiation of CPB is selective and more typical of non-traumatic cardiac arrest, cardiotoxic drug ingestion, and accidental hypothermia [5]. CPB for surgical repair of cardiac trauma has been reported in approximately 10% of cases [7]. Although repair of intracardiac lesions necessitates its use, application in free wall rupture is based on surgical judgment and complexity of the lesion [2,9]. Hendel and

Grant recommend CPB utilization for the following indications: massive bleeding with release of tamponade or need for considerable manipulation with risk for circulatory compromise [10]. In the present case, the large size of the atrial injury prohibited simultaneous hemostasis and repair in the absence of CPB. Cannulas were placed in the ascending aorta and femoral vein for initiation of CPB. Operating room resources were mobilized to the trauma bay and repair was carried out with running 4–0 prolene suture.

Coordination of care is essential to this and similar scenarios in which either multiple services or mass casualty triage is requisite. By improving communication between providers, Klein and Weigelt decreased the number of physicians involved and increased efficiency in polytrauma triage [11]. Given the need for hierarchical decision-making, surgeons represent integral members in guidance of the emergency team and effective triage processes. This case underscores the need for a “flight control tower” in the coordination of a successful outcome in which a multidisciplinary approach is required.

The present case demonstrates a unique application of CPB in the setting of BCI rupture repair in the emergency department of a tertiary facility. CPB should be considered within algorithms for bridge to definitive treatment of BCI with rupture at appropriate centers.

References

- [1] J.M. Schultz, D.D. Trunkey, Blunt cardiac injury, *Crit. Care Clin.* 20 (2004) 57–70.
- [2] R. Pretre, M. Chilcott, Blunt trauma to the heart and great vessels, *New Eng J Med* 336 (1997) 626–632.
- [3] Y.Y. Nan, M.S. Lu, K.S. Liu, et al., Blunt traumatic cardiac rupture: therapeutic options and outcomes, *Injury* 40 (2009) 938–945.
- [4] P.G. Teixeira, K. Inaba, D. Oncel, et al., Blunt cardiac rupture: a 5-year NTDB analysis, *J. Trauma* 67 (2009) 788–791.
- [5] H. Nakano, Y. Hirose, T. Mishima, S. Nakazawa, Y. Sato, K. Kobayashi, Emergency department initiation of percutaneous cardiopulmonary support for traumatic cardiac tamponade with coagulated pericardial effusion, *Injury Extra* 45 (2014) 29–31.
- [6] B.B. DeBerry, J.E. Lynch, J.M. Chernin, J.B. Zwischenberger, D.H. Chung, Successful management of pediatric cardiac contusion with extracorporeal membrane oxygenation, *J. Trauma* 63 (2007) 1380–1382.
- [7] W.C. Pevec, A.O. Udekwu, A.B. Peitzman, Blunt rupture of the myocardium, *Ann. Thorac. Surg.* 48 (1989) 139–142.
- [8] M. Al Ayyan, T. Aziz, A. El Sherif, O. Bekdache, Blunt cardiac injury: case report of salvaged traumatic right atrial rupture, *Ulus. Travma Acil Cerrahi Derg.* 21 (2016) 527–530.
- [9] B. Onan, R. Demirhan, K. Oz, I.S. Onan, Cardiac and great vessel injuries after chest trauma: our 10-year experience, *Ulus. Travma Acil Cerrahi Derg.* 17 (2011) 423–429.
- [10] P.N. Hendel, A.F. Grant, Blunt traumatic rupture of the heart. Successful repair of simultaneous rupture of the right atrium and left ventricle, *J. Thorac. Cardiovasc. Surg.* 81 (1981) 574–576.
- [11] J.S. Klein, J.A. Weigelt, Disaster management. Lessons learned, *Surg. Clin. North Am.* 71 (1991) 257–266.