



12-2015

# Post Operative Fungal Endophthalmitis Due to *Geotrichum candidum*

Thein Myint

University of Kentucky, [thein.myint3@uky.edu](mailto:thein.myint3@uky.edu)

Matthew J. Dykhuizen

University of Kentucky, [mdy222@uky.edu](mailto:mdy222@uky.edu)

Carolyn H. McDonald

University of Kentucky, [carolyn.mcdonald@uky.edu](mailto:carolyn.mcdonald@uky.edu)

Julie A. Ribes

University of Kentucky, [julie.ribes@uky.edu](mailto:julie.ribes@uky.edu)

**[Click here to let us know how access to this document benefits you.](#)**

Follow this and additional works at: [https://uknowledge.uky.edu/microbio\\_facpub](https://uknowledge.uky.edu/microbio_facpub)

 Part of the [Medical Immunology Commons](#), [Medical Microbiology Commons](#), and the [Molecular Genetics Commons](#)

## Repository Citation

Myint, Thein; Dykhuizen, Matthew J.; McDonald, Carolyn H.; and Ribes, Julie A., "Post Operative Fungal Endophthalmitis Due to *Geotrichum candidum*" (2015). *Microbiology, Immunology, and Molecular Genetics Faculty Publications*. 79.

[https://uknowledge.uky.edu/microbio\\_facpub/79](https://uknowledge.uky.edu/microbio_facpub/79)

This Article is brought to you for free and open access by the Microbiology, Immunology, and Molecular Genetics at UKnowledge. It has been accepted for inclusion in Microbiology, Immunology, and Molecular Genetics Faculty Publications by an authorized administrator of UKnowledge. For more information, please contact [UKnowledge@sv.uky.edu](mailto:UKnowledge@sv.uky.edu).

---

**Post Operative Fungal Endophthalmitis Due to *Geotrichum candidum***

**Notes/Citation Information**


Published in *Medical Mycology Case Reports*, v. 10, p. 4-6.

Crown Copyright © 2015 Published by Elsevier B.V. on behalf of International Society for Human and Animal Mycology

This is an open access article under the CC BY-NC-ND license (<http://creativecommons.org/licenses/by-nc-nd/4.0/>).

**Digital Object Identifier (DOI)**

<http://dx.doi.org/10.1016/j.mmcr.2015.11.001>



## Post operative fungal endophthalmitis due to *Geotrichum candidum*



Thein Myint<sup>a,\*</sup>, Matthew J. Dykhuizen<sup>b</sup>, Carolyn H. McDonald<sup>c</sup>, Julie A. Ribes<sup>c,d</sup>

<sup>a</sup> Division of Infectious Diseases, University of Kentucky, KY, USA

<sup>b</sup> Department of Ophthalmology, University of Kentucky, KY, USA

<sup>c</sup> Department of Microbiology, University of Kentucky, KY, USA

<sup>d</sup> Department of Pathology and Laboratory Medicine, University of Kentucky, KY, USA

### ARTICLE INFO

#### Article history:

Received 4 September 2015

Received in revised form

30 October 2015

Accepted 19 November 2015

Available online 1 December 2015

#### Keywords:

*Geotrichum candidum*

Endophthalmitis

### ABSTRACT

*Geotrichum* species have been rarely reported as the cause of sepsis, disseminated infection in immunosuppressed patients. The patient we describe developed indolent endophthalmitis four months after her routine right eye cataract surgery. The intraoperative sample from right vitreous fluid grew *Geotrichum candidum*. The patient underwent vitrectomy, artificial lens explantation and intravitreal injection of amphotericin B followed by oral voriconazole. Despite these interventions, she underwent enucleation. This is the first published case of *Geotrichum candidum* endophthalmitis.

© 2015 Published by Elsevier B.V. on behalf of International Society for Human and Animal Mycology This is an open access article under the CC BY-NC-ND license (<http://creativecommons.org/licenses/by-nc-nd/4.0/>).

### 1. Introduction

*Geotrichum* species are infrequently found as part of the normal flora in humans. It has been isolated as flora from a variety of sources including respiratory specimens, mouth, intestine, vagina, and skin [1].

*Geotrichum* species are usually non-pathogenic, but have been rarely reported to cause actual disease. Cases of sepsis, disseminated disease, and oral and cutaneous infections in immunocompromised hosts with hematologic malignancies or human immunodeficiency virus infections have been described [2–8]. There is one case report of traumatic joint infection in an immunocompetent patient [9].

This report describes a case of postoperative fungal endophthalmitis caused by *Geotrichum candidum* in a diabetic patient and discusses the potential antimicrobial therapies used to treat this organism.

### 2. Case

The patient was a 59-year-old female with hypertension, coronary artery disease status post coronary bypass graft surgery, hypothyroidism, diabetes complicated by proliferative diabetic retinopathy, and gastropathy. She underwent routine right eye cataract surgery followed by left eye cataract surgery a month later.

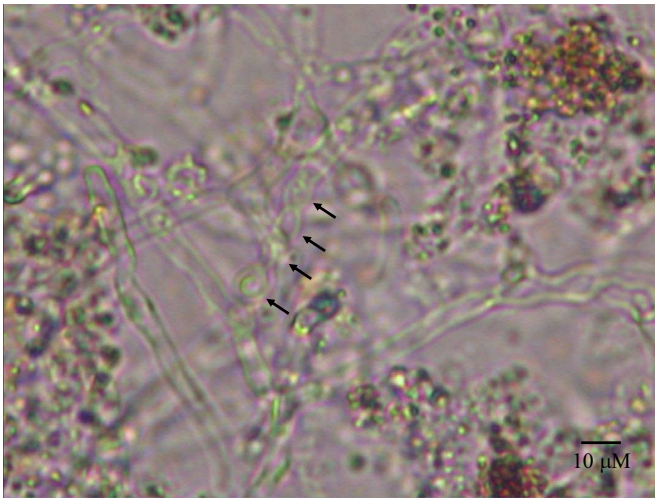
She initially had improvement in the vision of her right eye until about 3 months later when she started to have retro-orbital pain and blurred vision which was treated with topical eye drops (day 0 being the day of first symptom). She went back to her ophthalmologist approximately 45 days after development of her initial symptoms when the eye drops failed to correct her visual difficulties.

Vision in the right eye was limited to hand motions. An afferent pupillary defect was not noted. Intraocular pressure was elevated at 29 mmHg. The anterior segment examination of the right eye demonstrated a small corneal abrasion, shallow anterior chamber, and a mild hypopyon. A peripheral iridotomy was noted superiorly. The anterior segment findings limited visualization of the posterior pole. B-scan ultrasound demonstrated vitritis and no retinal detachment. A diagnosis of chronic post-operative endophthalmitis was made (Picture). Standard pars plana vitrectomy was completed without complication 76 days after her first symptoms. The vitrectomy fluid was opaque and brown. Samples of the vitreous cavity were sent to the laboratory for gram stain and microbiological studies. At the conclusion of the case, intravitreal injections of vancomycin, ceftazidime, and amphotericin B were administered. The KOH stain of right eye vitreous fluid showed numerous septate hyphae (Fig. 1). The patient was subsequently admitted for treatment 82 days after her first symptoms.

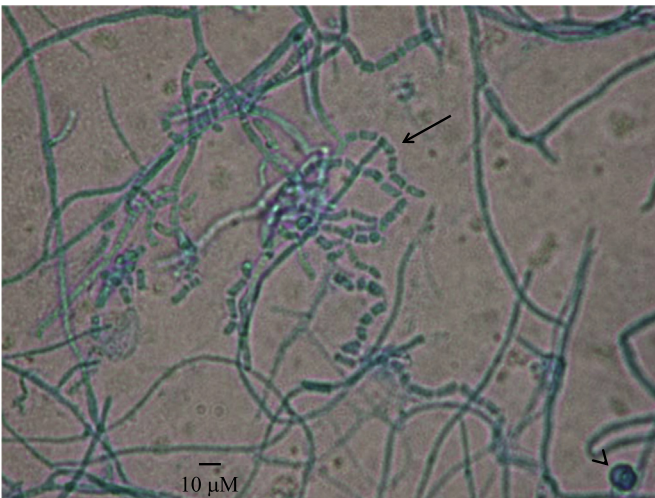
The patient was empirically treated with topical eye drops including Combigan (brimonidine and timolol) two times per day, polymyxin every six hours, Lumigan (Bimatoprost) daily, Durezol (difuprednate) every six hours. In addition, oral acetazolamide 250 mg twice daily, intravenous voriconazole 500 mg two times per day, and intravenous amphotericin B 3 mg/kg daily were given.

\* Corresponding author.

E-mail address: [thein.myint3@uky.edu](mailto:thein.myint3@uky.edu) (T. Myint).



**Fig. 1.** Direct KOH wet mount of ocular fluid. The ocular fluid contained brown granular material, hyphae measuring 6–8  $\mu\text{M}$  in width and chains of arthroconidia (arrows), measuring  $6 \times 8 \mu\text{M}$ .



**Fig. 2.** The organism on tape preparation from the Sabouraud dextrose agar stained with lacto-phenol-cotton-blue stain. The isolate grew as a septate, filamentous mycelium measuring 6–8  $\mu\text{M}$  in width, with rare chlamydospores (arrowhead). The hyphae fragmented into chains of arthroconidia (arrow) and individual cells.

Culture from the vitreous fluid grew a filamentous yeast-like mold that produced arthroconidia without blastoconidia. Urease was negative and sugar assimilation by API 20A identified the organism as *Geotrichum* species (API assimilation assay number 6042004), morphologically consistent with *G. candidum*. (Fig. 2). Automated blood cultures demonstrated no growth at 5 days, while the isolator blood culture demonstrated no growth at 21 days incubation. Following the positive vitrectomy, the patient returned for additional surgery.

The posterior chamber intraocular lens was explanted and additional amphotericin B and voriconazole were administered via intravitreal injection. A dose of cefazolin was injected subconjunctivally. Additionally, fungal cultures from the right eye vitreous cavity and right eye intraocular lens collected at the time of the second surgery, did not demonstrate fungal or bacterial growth. After 9 days of intravenous voriconazole, it was changed to oral voriconazole 300 mg twice daily. Intravenous amphotericin B was given for 15 days and stopped after the serum voriconazole level became therapeutic (3.8 mcg/ml).

The susceptibility testing was performed using the Etest strip method, for which there were no CLSI (Clinical and Laboratory

Standards Institute) interpretations. Voriconazole MIC was 0.125  $\mu\text{g}/\text{mL}$ , Itraconazole 6  $\mu\text{g}/\text{mL}$ , Fluconazole 128  $\mu\text{g}/\text{mL}$ , Amphotericin B 0.047  $\mu\text{g}/\text{mL}$ . She was admitted for 23 days and discharged on 105 days after her initial onset of symptoms with multiple eye drops and treated with oral voriconazole 300 mg twice daily for three months.

Despite aggressive therapy, the patient's eye became painful and the vision deteriorated to light perception. She underwent enucleation of the right eye with a Medpor implant three months after antifungal treatment, 195 days after her first symptoms. The pathology demonstrated acute and chronic inflammation with abscess formation with extensive granulation tissue. A retinal detachment was present with adherence to the iris and ciliary body. No persistence of fungal elements was detected on extensive examination of the tissue sections.

### 3. Discussion

To the best of our knowledge, this is the first published case of post-operative endophthalmitis caused by *G. candidum*. The genus *Geotrichum* is composed of 18 species. The most common species found in clinical specimens is *G. candidum*. *G. candidum* infections are overall very uncommon, presenting mainly as pulmonary or bronchopulmonary disease, but cutaneous, oral, and disseminated infections have also been noted [10]. Fewer than 100 cases have been reported between 1842 and 2006 [2,5–7,9,11–13]. Recent cases reflect disease as opportunistic infections in at risk patient populations [14].

Other case reports of human disease attributed to *Geotrichum* spp. reflect organisms no longer considered *Geotrichum* spp. including *Geotrichum clavatum* (reclassified as *Saprochaete clavate*) and *Geotrichum capitatum* (reclassified as *Blastoschizomyces capitatus*), which are predominantly found in Europe (particularly in Italy) and in patients with leukemia [8].

*G. candidum* is a ubiquitous filamentous yeast-like fungus commonly isolated from soil, air, water, milk, silage, plant tissues, digestive tract in humans and other mammals [14,15]. The young colonies of *G. candidum* are white, moist, yeast-like and easily picked up. Microscopically, it forms coarse true hyphae that segment into rectangular arthroconidia which vary in length (4–10  $\mu\text{m}$ ) [16]. The pattern of sugar assimilation, negative urease activity, and absence of blastoconidia produced along the hyphae, help to morphologically distinguish *Geotrichum* from *Trichosporon* spp. The findings for this patient's isolate were consistent with a diagnosis of *G. candidum* as the etiologic agent.

There are very limited data on the activity of antimicrobial agents against *G. candidum*. Voriconazole has been shown to have the lowest MIC of the azole drugs [17], although amphotericin B containing compounds have been the most widely reported therapies [2,5]. The susceptibility testing in our patient showed an amphotericin MIC of 0.04 mcg/ml, fluconazole 128 mcg/ml, itraconazole 6 mcg/ml, and voriconazole 0.125 mcg/ml. Even though she was given adequate treatment with 15 days of IV AmBisome and 3 months of voriconazole, her eye did not recover vision beyond light perception, despite histologic evidence of clearance of the infection.

The patient presented in this case did not have neutropenia, any documented underlying cancer or hematological malignancy, but instead had diabetes and surgical manipulation of the eye as the underlying risk factor for acquiring infection. *Geotrichum* endophthalmitis is a rare post operative fungal infection. It is probable that the organism was directly inoculated into the patient during the perioperative period surrounding the cataract procedure. Even with aggressive surgeries and systemic antifungal therapies, our patient failed to respond to treatment. Early

recognition and treatment of this disease might have changed the patient's outcome.

#### Conflict of interest

There are none

#### Ethical form

This patient expired. The patient's next of kin has no objection against publication.

#### Acknowledgments

None

#### Appendix A. Supplementary Information

Supplementary data associated with this article can be found in the online version at: <http://dx.doi.org/10.1016/j.mmcr.2015.11.001>.

#### References

- [1] D.H. Larone, *Medically Important Fungi: A Guide to Identification*, Wiley, New York, 2011.
- [2] A. Sfakianakis, K. Krasagakis, M. Stefanidou, S. Maraki, A. Koutsopoulos, D. Kofteridis, et al., Invasive cutaneous infection with *Geotrichum candidum*: sequential treatment with amphotericin B and voriconazole, *Med. Mycol.* 45 (2007) 81–84.
- [3] T.J. Henrich, F.M. Marty, D. a Milner, a R. Thorner, Disseminated *Geotrichum candidum* infection in a patient with relapsed acute myelogenous leukemia following allogeneic stem cell transplantation and review of the literature, *Transpl. Infect. Dis.* 11 (2009) 458–462.
- [4] G.S. Heinic, D. Greenspan, L.A. MacPhail, J.S. Greenspan, Oral *Geotrichum candidum* infection associated with HIV infection. A case report, *Oral Surg. Oral Med. Oral Pathol.* 73 (1992) 726–728.
- [5] N. Andre, C. Coze, J.C. Gentet, R. Perez, J.L. Bernard, *Geotrichum candidum* septicemia in a child with hepatoblastoma, *Pediatr. Infect. Dis. J.* 23 (2004) 86.
- [6] A. Bonifaz, D. Vázquez-González, B. Macías, F. Paredes-Farrera, M. A. Hernández, J. Araiza, et al., Oral geotrichosis: report of 12 cases, *J. Oral Sci.* 52 (2010) 477–483.
- [7] J. Jagirdar, S.A. Geller, E.J. Bottone, *Geotrichum candidum* as a tissue invasive human pathogen, *Hum. Pathol.* 12 (1981) 668–671.
- [8] C. Girmenia, L. Pagano, B. Martino, D. D'Antonio, R. Fanci, G. Specchia, et al., Invasive infections caused by *Trichosporon* species and *Geotrichum capitatum* in patients with hematological malignancies: a retrospective multicenter study from Italy and review of the literature, *J. Clin. Microbiol.* 43 (2005) 1818–1828.
- [9] D.B. Hrdy, N.N. Nassar, M.G. Rinaldi, Traumatic joint infection due to *Geotrichum candidum*, *Clin. Infect. Dis.* 20 (1995) 468–469.
- [10] D.R. Hospenthal, Rinaldi, G. Michael, *Diagnosis and Treatment of Human Mycoses (Infectious Disease)*, (2007) 428.
- [11] T.W. Sheehy, B.K. Honeycutt, J.T. Spencer, *Geotrichum* septicemia, *J. Am. Med. Assoc.* 235 (1976) 1035–1037.
- [12] K.P. Ng, T.S. Soo-Hoo, M.T. Koh, P.W. Kwan, Disseminated *Geotrichum* infection, *Med. J. Malays.* 49 (1994) 424–426.
- [13] A.R. Ghamande, F.B. Landis, G.L. Snider, *Bronchial geotrichosis* with fungemia complicating bronchogenic carcinoma, *Chest* 59 (1971) 98–101.
- [14] I. Pottier, S. Gente, J.P. Vernoux, M. Gueguen, Safety assessment of dairy microorganisms: *Geotrichum candidum*, *Int. J. Food Microbiol.* 126 (2008) 327–332.
- [15] M.H. Miceli, J.A. Diaz, S.A. Lee, Emerging opportunistic yeast infections, *Lancet Infect. Dis.* 11 (2011) 142–151.
- [16] E.W. Koneman, *Koneman's Color Atlas and Textbook of Diagnostic Microbiology*, 6th ed., Lippincott Williams & Wilkins, Philadelphia, 2006.
- [17] O. Zaragoza, A.C. Mesa-Arango, A. Gomez-Lopez, L. Bernal-Martinez, J. L. Rodriguez-Tudela, M. Cuenca-Estrella, Process analysis of variables for standardization of antifungal susceptibility testing of nonfermentative yeasts, *Antimicrob. Agents Chemother.* 55 (2011) 1563–1570.