



**Peer-Reviewed Case Report and Literature Review**

# Fulminant Necrotizing Eosinophilic Myocarditis: A Case Report and Comprehensive Literature Review

**Bennet George<sup>1</sup>, Matthew Hager<sup>2</sup>, Virgilius Cornea<sup>3</sup>, William O'Connor<sup>3</sup>, and Maya Guglin<sup>1\*</sup>**

<sup>1</sup> Division of Cardiology

<sup>2</sup> Department of Internal Medicine

<sup>3</sup> Department of Pathology

University of Kentucky, Lexington, KY

\* Corresponding author: [maya.guglin@uky.edu](mailto:maya.guglin@uky.edu)

Citation: George, B et al.(2016).  
" Fulminant Necrotizing  
Eosinophilic Myocarditis: A Case  
Report and Comprehensive  
Literature Review"  
*The VAD Journal*, 2. doi:  
<https://doi.org/10.13023/VAD.2016.26>

Editor-in-Chief: Maya Guglin,  
University of Kentucky

Received: August 24, 2016

Accepted: November 3, 2016

Published: November 5, 2016

© 2016 The Author(s). This is an open access article published under the terms of the [Creative Commons Attribution-NonCommercial 4.0 International License](https://creativecommons.org/licenses/by-nc/4.0/) (<https://creativecommons.org/licenses/by-nc/4.0/>), which permits unrestricted non-commercial use, distribution, and reproduction in any medium, provided that the original author(s) and the publication source are credited.

Funding: Not applicable

Competing interests: Not applicable

## Abstract

Acute eosinophilic myocarditis is a relatively rare disorder with serious morbidity and mortality. Due to its infrequency, standardized management guidelines are wanting. We present a case of acute, necrotizing eosinophilic myocarditis requiring several levels of critical care. We reviewed similar cases reported in the literature to highlight common clinical features, describe natural disease course and associated complications, and review varying approaches to medical therapy.

**Keywords:** Eosinophilic myocarditis, mechanical circulatory support, ECMO

## Introduction

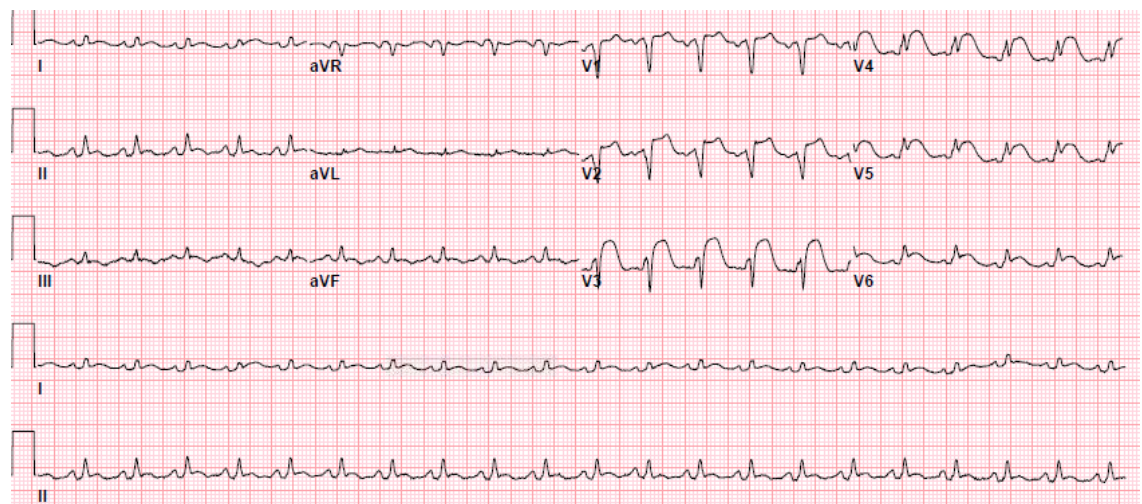
Acute necrotizing eosinophilic myocarditis is a rare and often fatal condition that can manifest as severely decompensated heart failure with biopsy revealing marked eosinophilic infiltration. We present a case of a 40-year-old male presenting with cardiogenic shock who transiently required veno-arterial extracorporeal membrane oxygenation while the diagnosis of acute necrotizing



eosinophilic myocarditis was made and treatment with immunosuppressive therapy was started.

### Case Presentation

A 40-year-old African American male presented to his primary care physician with three days of subjective fevers, exertional dyspnea, and a non-productive cough. Past medical history was notable for gout managed with intermittent diclofenac. He had no reported allergies. Because of hypoxia on room air, he was referred to a local emergency room where chest x-ray demonstrated bilateral opacifications and he was admitted for treatment of community-acquired pneumonia. On the night of admission, respiratory failure ensued requiring mechanical ventilation. Subsequent electrocardiogram (ECG) performed showed concerns for anterior ST-elevation myocardial infarction (Figure 1). Initial troponin-I was 29 ng/mL. He was urgently taken to the cardiac catheterization lab but had no evidence of flow-limiting coronary artery disease. The patient's clinical course continued to deteriorate necessitating intubation, empiric antibiotics, use of vasopressors and inotropes, and eventual placement of an intra-aortic balloon pump (IABP). Given the complexity of his medical illness, the patient was transferred to our institution for resumption of care. On the night of transfer, the patient experienced a five-minute episode of pulseless electrical activity arrest, which devolved into monomorphic ventricular tachycardia (VT) with pulse requiring defibrillation to restore normal sinus rhythm. Subsequent labs were remarkable for a white blood cell count of 19 K/uL (peripheral eosinophils within normal limits), BUN of 60 mg/dL, creatinine of 3.2 mg/dL, aspartate aminotransferase of 969 U/L, alanine aminotransferase of 723 U/L, serum lactate of 2.8 mmol/L, and N-terminal pro b-type natriuretic peptide level of 42,000 pg/mL.



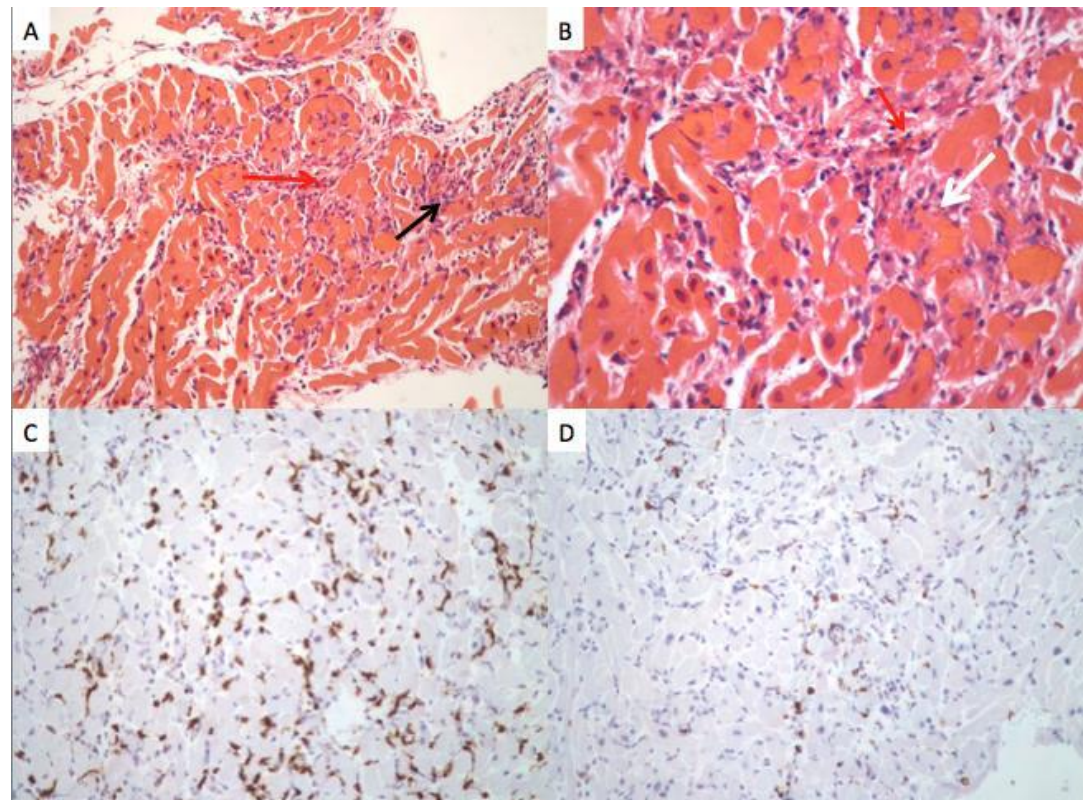
**Figure 1.** Electrocardiogram demonstrating sinus tachycardia and ST elevation in the anterior and anterolateral precordial leads suggestive of acute infarction

On day two, the patient's oxygen requirements continued to increase, ultimately necessitating maximal ventilator support. Transthoracic echocardiogram showed



reduced left ventricular function with an estimated ejection fraction of 30-35%. Aggressive diuresis over the next 24 hours led to successful removal of the IABP and weaning of dobutamine. On the fourth day of hospitalization, the patient's worsening clinical condition ultimately required veno-arterial extracorporeal membrane oxygenation (ECMO). A Maquet RotoFlow ECMO circuit was utilized with 17-French arterial and 25-French venous cannulation. Initial flows were set at 5.3 liters per minute. Concomitant right-heart catheterization with endomyocardial biopsy was performed. On the night the patient was placed on ECMO, he developed persistent ventricular tachycardia treated with multiple defibrillations (thirty over a twelve-hour period), amiodarone pharmacotherapy, and transcutaneous pacing. Despite his electrical instability, the patient was maintained successfully on ECMO.

Endomyocardial biopsy results returned the following day revealing inflammatory infiltrates with mixed T and B cell lymphocytes (predominantly of T-cell population) and eosinophils comprising 60-70% of the myocardial tissue (Figure 2).



**Figure 2.** Endomyocardial biopsy findings

- A. Hematoxylin and eosin (H&E), 200x: increased interstitial inflammatory infiltrate (black arrow) with increased eosinophils (red arrow).
- B. H&E, 400x demonstrating degranulated eosinophils (red arrow) and myocyte necrosis (white arrow)
- C. CD-3 immunohistochemical stain, 200x highlights T-cell lymphocytes
- D. CD-20 immunohistochemical stain, 200x marks B-cell lymphocytes



Overt myocyte necrosis was noted in roughly 20% of the tissue specimens. The patient was started on immunosuppressive therapy with high-dose steroids along with azathioprine. Over the course of his hospitalization, prednisone dosing was gradually weaned.

Transthoracic echocardiography was performed on multiple occasions throughout the patient's hospital course. Just prior to initiation of high-dose steroid therapy, his left ventricular ejection fraction (LVEF) was estimated at 5% with spontaneous echo contrast in the left ventricular (LV) cavity and absent aortic valve opening. After initiating steroid therapy, LV function quickly improved. With appropriate medical therapy, ventilator support was removed on day 11 and ECMO was discontinued on day 12 of hospitalization. Subsequent ECGs demonstrated normal sinus rhythm with poor R-wave progression in the anterolateral precordial leads.

Several complications occurred over the patient's hospital course. Despite adequate diuresis, blood urea nitrogen levels rose well above 200 mg/dL with resultant epistaxis and ECMO insertion site bleeding from presumed platelet dysfunction. The patient required multiple transfusions along with continuous renal replacement therapy for filtration of toxins. Kidney function recovered prior to discharge. Furthermore, the patient's white blood cell count steadily decreased from 33 K/uL on day 17 to 1.3 K/uL on day 20 with an absolute neutrophil count of 500 k/uL. Imuran was discontinued due to neutropenia and the leukopenia eventually resolved. Perhaps the most concerning complication was the development of a necrotizing pneumonia with several large cavitory areas resulting in a spontaneous pneumothorax. On day 42 of hospitalization, re-intubation was required along with chest tube placement. Bronchoalveolar lavage was positive for *Candida albicans* and therapy with fluconazole was started. Despite several complications, the patient continued to improve and recovered enough to be discharged to a rehabilitation facility on day 72 of hospitalization.

## **Discussion**

Eosinophilic myocarditis is a rare condition characterized by myocardial inflammation with eosinophilic infiltration. The disease is most commonly seen in hypereosinophilic syndrome (defined as an absolute eosinophil count greater than  $1.5 \times 10^9/L$ ), with up to 60% of patients having myocardial involvement<sup>1</sup>. This form of eosinophilic myocarditis is commonly chronic, occurring in the presence of extra-cardiac symptoms with notable eosinophilia in peripheral blood. Established etiologic factors include hypersensitivity reactions to medications, helminths, vaccines (such as smallpox, meningococcal, and hepatitis B), hypereosinophilic syndrome, tropical endomyocardial fibrosis, transplant rejection, certain vasculitides such as Churg-Strauss, and some malignancies. Diclofenac exposure was suspected to be the culprit in our patient, though methyl dopa, hydrochlorothiazide, ampicillin, furosemide, digoxin, tetracycline, aminophylline, phenytoin, benzodiazepines, and tricyclic antidepressants are more commonly recognized offending medications<sup>2</sup>.

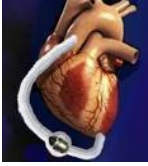

Necrosis is an uncommon finding in the setting of eosinophilic myocarditis. Eosinophilic necrotizing myocarditis often has a fulminant course with many diagnoses made posthumously via autopsy<sup>1,3</sup>. Prior autopsy series noted that only 37 out of 69 autopsied hearts with eosinophilic myocarditis demonstrated a focus of necrosis. Though myocarditis was the reported cause of death in many of these patients, none demonstrated extensive necrosis by histology<sup>4</sup>. It is important to note that as many diagnoses are made post-humously, endomyocardial biopsy may miss areas of eosinophilic infiltration adding another wrinkle to the challenging diagnosis. This entity has a rapidly progressive course with profound hemodynamic compromise, often culminating in cardiogenic shock. A high index of suspicion is needed as death may occur days or weeks after the onset of symptoms, with or without extra-cardiac involvement<sup>3</sup>. Our patient presented to an outside facility and treated for community acquired pneumonia. The possibility of eosinophilic pneumonia could have been a subtle clue towards our diagnosis. Death may occur days or weeks after the onset of symptoms, with or without extra-cardiac involvement<sup>3</sup>. It is notable that even among patients with fulminant myocarditis, most cases are lymphocytic. In the series of eight cases in a single institution, only one case of fulminant myocarditis was of eosinophilic (as opposed to lymphocytic) infiltration of the myocardium<sup>5</sup>.

Due to the rarity of necrotizing eosinophilic myocarditis, evidence-based treatment guidelines are not available. In this case, once a diagnosis was confirmed via endomyocardial biopsy, a literature search was conducted for case reports of patients with similar presentation and pertinent features – including natural disease course and prognosis, well-described complications, optimal treatment, and most importantly, dose and duration of steroid therapy.

Table 1 displays a series of cases of myocardial eosinophilic infiltration and extensive necrosis confirmed on pathology (biopsy or autopsy). Cases with mild focal necrosis were not included. A case in which myocarditis developed after withdrawal of steroids used for other conditions was excluded<sup>6</sup>. A case of myocarditis in a patient with a pre-existent severe cardiomyopathy with ejection fraction of 20% was also excluded<sup>7</sup>.

Twenty case reports were included in our search and with our patient; we reviewed 21 cases of fulminant, necrotizing, eosinophilic myocarditis. Out of 21 patients, 15 survived and 6 died. This cannot serve as an estimate of prognosis because cases with more favorable outcomes were reported and published with higher frequency. We can presume, however, that the notion of necrotizing, eosinophilic myocarditis as a post-mortem diagnosis is largely untrue. Male and female patients were represented evenly (12 men and 9 women). Electrocardiogram findings were reported in 16 cases. Of these 16 ECGs, ST elevation was present in 11 cases (68.8%). Due to this finding, many patients underwent unnecessary coronary angiography, which was uniformly unremarkable as the ST elevation was related to the infiltrative process with resultant myocardial necrosis. Coronary angiography was understandably difficult to avoid during initial management of these patients given the concern for acute coronary syndrome. More importantly, six patients (37.5% of those with reported ECG findings) experienced sustained ventricular tachycardia or ventricular fibrillation, and, of these, two did not survive. The high



rate of fatal arrhythmias, which can be poorly responsive to conventional therapies such as defibrillation and antiarrhythmics, makes a case for the liberal use of mechanical circulatory support. Mechanical circulatory support seems to be the only treatment modality that can sustain a patient through a prolonged period of electrical instability.

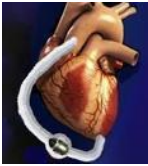Elevated cardiac enzymes were present in each case where enzymes were collected, and therefore were not included in our table. The presence or absence of peripheral eosinophilia was mentioned in all but one case. Eosinophilia was present in 12 cases and absent in 8, including ours. Among the 15 survivors, peripheral eosinophilia was present in at least 8 patients (57.1%) with one case not reporting such a finding. Four (66.6%) of the deceased patients had peripheral eosinophilia. Although the sample size is undeniably small, it seems unlikely that peripheral eosinophilia has a major bearing on prognosis. There seems to be no relationship among peripheral eosinophil count, the extent of eosinophilic infiltrate, and clinical symptoms<sup>8</sup>. Echocardiogram invariably demonstrates profound left ventricular systolic dysfunction. Even when patients were admitted with normal or mildly impaired left ventricular function, it deteriorated within a matter of hours or days. Interestingly, thickening of the left ventricular wall, resembling hypertrophy, was noted in several cases and was likely related to eosinophilic infiltration. This feature, along with systolic dysfunction, can be reversible with successful treatment<sup>1</sup>. In some cases, thickening reached nearly 2 cm<sup>3</sup>. Spontaneous echo contrast was noted in the left ventricular cavity by one group of authors<sup>9</sup> (as in our patient). Apical thrombus has also been reported<sup>10</sup>. Both findings are consistent with a low flow state. Cardiac imaging, predominantly echocardiography, was performed at random intervals at the discretion of the individual authors. We performed serial echocardiograms throughout our patient's hospital course. From our experience, and from other reports, once the initial response to steroids was positive, near normal or normal ventricular function was restored within 21 days<sup>10-12</sup>, regardless of the initial severity of left ventricular dysfunction. Due to difficult logistic reasons, a cardiac MRI was unable to be performed. Though often difficult to obtain in a critical care setting, it is possible that CMR features of eosinophilic myocarditis could help guide initiation of steroid therapy and consideration of this imaging modality is warranted.

In terms of extra-cardiac complications, our patient developed severe renal dysfunction and required renal replacement therapy for several weeks. Within our case series, only one other patient was reported to have acute kidney injury and required continuous renal replacement therapy for several days<sup>12</sup>. Our patient was the only one to develop a cavitary necrotizing pneumonia requiring prolonged mechanical ventilation which may have been related to the dose and tapering of steroids.



**Table 1 – Cases of Eosinophilic Myocarditis with Extensive Necrosis**

Author	Age and Gender	ECG findings	Peri- pheral eosino- philia	MCS	Echocardiogram Findings	Outcome	Steroid Management
Aggarwal <sup>13</sup>	46, male	ST elevation	No	IABP for 6 days	Severe LV systolic dysfunction, thickening of ventricular walls. Normalization in 2 weeks.	Survived	Methylprednisolone 1 g/day IV for 2 days, then oral tapering dose
Watanabe <sup>16</sup>	55, male		No	IABP	LVEF of 23% with increased wall thickness. Improved to 44% in 3 days. Normal in 2 weeks.	Survived	Methylprednisolone 1 g/day IV for 3 days, then prednisone 60 mg/day for 2 weeks
Al Ali <sup>17</sup>	50, male	ST elevation in inferolateral leads	Yes	None	LVEF 45%. Normal in 2 months	Survived	Prednisone 1 mg/kg/day PO
Al Ali <sup>17</sup>	26, male			None	LVEF 20% with normal RV/LV size. Normal in 4 months	Survived	Prednisone 1 mg/kg/day PO
Corradi <sup>15</sup>	23, female	Non-specific ST-T wave changes	Yes		LVEF 20% with LV dilatation	Survived	Methylprednisolone 1 g/day IV for 3 days, then prednisone 1 mg/kg/day PO with taper over 1 year
Allen <sup>12</sup>	48, female	Diffuse ST elevations; sustained VT	No	ECMO for 5 days	Moderate-severe biventricular dysfunction, normal RV/LV sizes. Normalization in 5 days	Survived	Methylprednisolone 1 g/day IV for 3 days, then prednisone 1 mg/kg/day PO with taper over 6 weeks
Cooper <sup>1</sup>	47, female	ST elevation V1-V3; sustained VF/VT	Yes	BiVAD for 2 weeks	LVEF 25%. Improved to 45% in 2 weeks	Survived	Methylprednisolone 10 mg/kg/day for 3 days, then prednisone 1 mg/kg PO daily, then decreased to 5 mg daily after 4 weeks
Enriquez <sup>18</sup>	65, male	ST elevation V1-V3	Yes	None	LVEF 30-35%. Normalization in 6 months	Survived	Methylprednisolone 0.5 g/day IV, then prednisone 1 mg/kg/day PO at tapering dose
Thambidora <sup>9</sup>	54, male	ST elevation in anterolateral leads	Yes	None	LVEF 30-35%, increased wall thickness, "smoke". Slight improvement in 1 week. Normal at 6 months	Survived	Methylprednisolone 300 mg/day IV for 1 week, then prednisone 60 mg/day PO for 1 week, followed by oral taper over 6 months
Galiuto <sup>10</sup>	67, female	ST elevation V2-V6	Yes	None	LVEF 35% with LV dilation and apical thrombus. Improved to 70% in 1 week	Survived	Prednisone 60 mg PO daily for 2 weeks followed by taper to 10 mg every other day before stopping at 2 months
Getz <sup>19</sup>	41, female	ST elevation inferiorly and anteriorly	No	None	Moderate LV dysfunction, increased wall thickness, dilated and hypertrophied RV with severe dysfunction.	Survived	Methylprednisolone 1 g/day IV for 3 days, then prednisone 60 mg/day PO
Huntgeburth <sup>20</sup>	55, female	ST abnormality in lateral leads	Yes	None	LVEF 19% with LV dilatation. LVEF improved to 43% in 4 months	Survived	Prednisolone 75 mg/day PO for 5 days tapered to 10 mg/day
Khabbaz <sup>11</sup>	19, female		Yes	ECMO for 10 days	LVEF < 10%, RV/LV dilatation. Improvement in 6 days and normalization in 10 days	Survived	Steroids
Kohout <sup>14</sup>	37, male	ST elevation in V1-V4 with VF	No	LVAD for 1 month	LVEF 10% with increased wall thickness and RV dilatation with hypokinesia. Normalization in 1 month.	Survived	Methylprednisolone 1 g/day IV for 3 days, then prednisone PO tapering for an additional 3 days (60 mg/day, 40 mg/day, and 20 mg/day)
Hyogo <sup>21</sup>	41, male	Right bundle branch block, posterior fascicular block, VT/VF	Yes	None	LVEF 28% with increased wall thickness	Died	None
Arsenovic <sup>4</sup>	41, male		Yes			Died	None
Herzog <sup>3</sup>	22, male	Left bundle branch block, VF	Yes		Global systolic dysfunction by M-mode and increased wall thickness	Died	None
Herzog <sup>3</sup>	47, male	Right bundle branch block	Yes			Died	None
Adamson <sup>22</sup>	51, female	ST elevation V1-V4, VT	No	None	LVEF 25% with increased wall thickness	Died	
Fragkouli <sup>23</sup>	66, female	ST elevation V3-V5	No	None	LVEF 25% with mildly increased wall thickness	Died	None



It seems clear from the combined experience within our case review, that high-dose steroids are a mandatory treatment for necrotizing eosinophilic myocarditis. There was no single case of survival in patients who did not receive high-dose steroids. Methylprednisolone or prednisone should be given as soon as the diagnosis is confirmed or even suspected. The variability of doses is reflected in Table 1. Methylprednisolone 1 g/day intravenously appears to be the most frequently used dose, although some authors gave lower doses. In the only case in which the authors opted to start with oral prednisone, the degree of left ventricular dysfunction was the mildest (EF of 35%)<sup>10</sup>. Of note, the Myocarditis Treatment Trial, demonstrated a lack of benefit of corticosteroids in acute myocarditis<sup>8</sup>. However, this is not applicable to our series of patients, as only those meeting the Dallas criteria (with lymphocytic as opposed to eosinophilic infiltration of myocardium) were included in the trial.

Other steroid-sparing agents, such as azathioprine in our patient, were used in other cases<sup>13</sup>. It is unclear whether steroids are sufficient or if other agents can contribute to management success. Cooper et al added mycophenolate mofetil and then sirolimus when steroids were decreased to prednisone 5 mg/day<sup>1</sup>. Interestingly, this was the only case with partial recurrence of myocarditis.

There does not seem to be any agreement regarding the rapidity of steroid tapering. Based on our collection of case reports, relapse is uncommon after initial progress is achieved. The only exception was a temporary decrease in ejection fraction (after initial complete recovery) to 40% months later<sup>1</sup>. There does not seem to be any agreement regarding the rapidity of steroid tapering. Based on our collection of case reports, relapse is uncommon after initial progress is achieved. The only exception was a temporary decrease in ejection fraction (after initial complete recovery) to 40% months later<sup>14</sup>. We were more cautious with our steroid taper and the necrotizing pneumonia our patient developed could be a consequence of this. On the other hand, Corradi et al tapered prednisone over one year<sup>15</sup>. Though there is a lack of randomized evidence, it seems that tapering steroids to complete discontinuation in two to four weeks is reasonable.

Mechanical circulatory support in the form of intra-aortic balloon pump (3 cases) or extracorporeal membrane oxygenation (3 cases including ours), or ventricular assist devices (2 cases) was used in a total of 7 cases. A balloon pump was followed by a ventricular assist device in one case<sup>1</sup>. The time of support ranged from 3 days to one month. All patients, regardless of the type of mechanical support, ultimately survived.

## **Conclusion**

Fulminant eosinophilic necrotizing myocarditis is a rare condition rapidly progressing to hemodynamic compromise including cardiogenic shock and cardiac arrest from sustained ventricular arrhythmias. It may have an excellent prognosis if aggressively treated in a timely manner with high doses of steroids and mechanical circulatory support if needed. The timely diagnosis by endomyocardial biopsy is critical. Empiric treatment while awaiting pathology results is justified.





Mechanical circulatory support should not be delayed, as it may be lifesaving, especially in the case of refractory ventricular tachycardia/fibrillation. Complete cardiac recovery can occur in a matter of days. Weaning of steroids can be done rapidly, within several weeks, to avoid steroid-related complications.

## References

1. Cooper LT and Zehr KJ. Biventricular assist device placement and immunosuppression as therapy for necrotizing eosinophilic myocarditis. *Nat Clin Pract Cardiovasc Med.* 2005;2:544-8.
2. Burke AP, Saenger J, Mullick F and Virmani R. Hypersensitivity myocarditis. *Arch Pathol Lab Med.* 1991;115:764-9.
3. Herzog CA, Snover DC and Staley NA. Acute necrotizing eosinophilic myocarditis. *Br Heart J.* 1984;52:343-8.
4. Arsenovic N, Sheehan L, Clark D and Moreira R. Fatal carbamazepine induced fulminant eosinophilic (hypersensitivity) myocarditis: emphasis on anatomical and histological characteristics, mechanisms and genetics of drug hypersensitivity and differential diagnosis. *J Forensic Leg Med.* 2010;17:57-61.
5. Chau EM, Chow WH, Chiu CS and Wang E. Treatment and outcome of biopsy-proven fulminant myocarditis in adults. *Int J Cardiol.* 2006;110:405-6.
6. Hayashi S, Furuya S and Imamura H. Fulminant eosinophilic endomyocarditis in an asthmatic patient treated with pranlukast after corticosteroid withdrawal. *Heart.* 2001;86:E7.
7. Fung E, Fong MW, Correa AJ, Yoon AJ and Grazette LP. Fulminant eosinophilic myocarditis following ICD implantation in a patient with undisclosed nickel allergy. *Int J Cardiol.* 2015;203:1018-1019.
8. Mason JW, O'Connell JB, Herskowitz A, Rose NR, McManus BM, Billingham ME and Moon TE. A clinical trial of immunosuppressive therapy for myocarditis. The Myocarditis Treatment Trial Investigators. *N Engl J Med.* 1995;333:269-75.
9. Thambidorai SK, Korlakunta HL, Arouni AJ, Hunter WJ and Holmberg MJ. Acute eosinophilic myocarditis mimicking myocardial infarction. *Tex Heart Inst J.* 2009;36:355-7.
10. Galiuto L, Enriquez-Sarano M, Reeder GS, Tazelaar HD, Li JT, Miller FA, Jr. and Gleich GJ. Eosinophilic myocarditis manifesting as myocardial infarction: early diagnosis and successful treatment. *Mayo Clin Proc.* 1997;72:603-10.
11. Khabbaz Z, Grinda JM and Fabiani JN. Extracorporeal life support: an effective and noninvasive way to treat acute necrotizing eosinophilic myocarditis. *J Thorac Cardiovasc Surg.* 2007;133:1122-3; author reply 1123-4.
12. Allen SF, Godley RW, Evron JM, Heider A, Nicklas JM and Thomas MP. Acute necrotizing eosinophilic myocarditis in a patient taking *Garcinia cambogia* extract successfully treated with high-dose corticosteroids. *Can J Cardiol.* 2014;30:1732 e13-5.
13. Aggarwal A, Bergin P, Jessup P and Kaye D. Hypersensitivity myocarditis presenting as cardiogenic shock. *J Heart Lung Transplant.* 2001;20:1241-4.
14. Kohout J, Ferdinand FD, Imaizumi S, Holmes EC and Samuels LE. A rare case of acute necrotizing eosinophilic myocarditis: bridge to recovery with ventricular assist device support. *J Thorac Cardiovasc Surg.* 2006;132:965-6.



15. Corradi D, Vaglio A, Maestri R, Legname V, Leonardi G, Bartoloni G and Buzio C. Eosinophilic myocarditis in a patient with idiopathic hypereosinophilic syndrome: insights into mechanisms of myocardial cell death. *Hum Pathol.* 2004;35:1160-3.
16. Watanabe N, Nakagawa S, Fukunaga T, Fukuoka S, Hatakeyama K and Hayashi T. Acute necrotizing eosinophilic myocarditis successfully treated by high dose methylprednisolone. *Jpn Circ J.* 2001;65:923-6.
17. Al Ali AM, Straatman LP, Allard MF and Ignaszewski AP. Eosinophilic myocarditis: case series and review of literature. *Can J Cardiol.* 2006;22:1233-7.
18. Enriquez A, Castro P, Gabrielli L, Braun S, Verdejo H, Cordova S and Van der linde Rosemberg V. Acute necrotizing eosinophilic myocarditis presenting as ST-elevation myocardial infarction: a case report. *Can J Cardiol.* 2011;27:870 e1-3.
19. Getz MA, Subramanian R, Logemann T and Ballantyne F. Acute necrotizing eosinophilic myocarditis as a manifestation of severe hypersensitivity myocarditis. Antemortem diagnosis and successful treatment. *Ann Intern Med.* 1991;115:201-2.
20. Huntgeburth M, Lindner M, Fries JW and Hoppe UC. Hypereosinophilic syndrome associated with acute necrotizing myocarditis and cardiomyopathy. *Z Kardiol.* 2005;94:761-6.
21. Hyogo M, Kamitani T, Oguni A, Kawasaki S, Miyanaga H, Takahashi T, Kunishige H and Andachi H. Acute necrotizing eosinophilic myocarditis with giant cell infiltration after remission of idiopathic thrombocytopenic purpura. *Intern Med.* 1997;36:894-7.
22. Adamson R, Yazici Y, Katz ES, Greisman SG and Steiger D. Fatal acute necrotizing eosinophilic myocarditis temporally related to use of adalimumab in a patient with relapsing polychondritis. *J Clin Rheumatol.* 2013;19:386-9.
23. Fragkouli K, Mitselou A, Boumba V, Michalis L and Vougiouklakis T. An autopsy case of necrotizing eosinophilic myocarditis causing left ventricular wall rupture. *Forensic Sci Med Pathol.* 2011;7:350-4.