University of Kentucky
UKnowledge

Gill Heart & Vascular Institute Faculty Publications

Heart & Vascular

11-17-2021

ST-Segment Elevation in a Patient With Nausea, Vomiting, and Intracerebral Hemorrhage

Ranjan Banerjee
University of Kentucky, Ranjan.Banerjee@uky.edu

Dustin Hillerson
University of Kentucky

Steve W. Leung
University of Kentucky, steve.leung@uky.edu

Vincent L. Sorrell
University of Kentucky, v.sorrell@uky.edu

Follow this and additional works at: https://uknowledge.uky.edu/heart_facpub

Part of the Cardiology Commons

Right click to open a feedback form in a new tab to let us know how this document benefits you.

Repository Citation

Banerjee, Ranjan; Hillerson, Dustin; Leung, Steve W.; and Sorrell, Vincent L., "ST-Segment Elevation in a Patient With Nausea, Vomiting, and Intracerebral Hemorrhage" (2021). *Gill Heart & Vascular Institute Faculty Publications*. 32.
https://uknowledge.uky.edu/heart_facpub/32

This Article is brought to you for free and open access by the Heart & Vascular at UKnowledge. It has been accepted for inclusion in Gill Heart & Vascular Institute Faculty Publications by an authorized administrator of UKnowledge. For more information, please contact UKnowledge@lsv.uky.edu.

ST-Segment Elevation in a Patient With Nausea, Vomiting, and Intracerebral Hemorrhage

Digital Object Identifier (DOI)
https://doi.org/10.1016/j.jaccas.2021.09.010

Notes/Citation Information
Published in *JACC: Case Reports*, v. 3, issue 16.

© 2021 The Authors

This is an open access article under the CC BY-NC-ND license (https://creativecommons.org/licenses/by-nc-nd/4.0/).

This article is available at UKnowledge: https://uknowledge.uky.edu/heart_facpub/32

JACC: CASE REPORTS VOL. 3, NO. 16, 2021
© 2021 THE AUTHORS. PUBLISHED BY ELSEVIER ON BEHALF OF THE AMERICAN COLLEGE OF CARDIOLOGY FOUNDATION. THIS IS AN OPEN ACCESS ARTICLE UNDER THE CC BY-NC-ND LICENSE (http://creativecommons.org/licenses/by-nc-nd/4.0/).

IMAGING VIGNETTE

BEGINNER

ECG CHALLENGE

ST-Segment Elevation in a Patient With Nausea, Vomiting, and Intracerebral Hemorrhage

Ranjan Banerjee, MD, Dustin Hillerson, MD, Steve W. Leung, MD, Vincent L. Sorrell, MD

ABSTRACT

A 60-year-old man who presented with nausea, vomiting, and intracerebral hemorrhage developed inferior ST-segment elevation and angina. Coronary angiography showed no coronary obstruction. The patient was found to have a small bowel obstruction causing superior translocation of the heart. Relief of obstruction caused immediate resolution of electrocardiographic changes and symptoms. (**Level of Difficulty: Beginner.**)
(J Am Coll Cardiol Case Rep 2021;3:1727–1729) © 2021 The Authors. Published by Elsevier on behalf of the American College of Cardiology Foundation. This is an open access article under the CC BY-NC-ND license (http://creativecommons.org/licenses/by-nc-nd/4.0/).

A 60-year-old man with a history of hydrocephalus with ventriculoperitoneal shunt presented with 1 day of recurrent nausea and vomiting and was found to have a small intraventricular hemorrhage noted on computed tomography (CT) of the head. Following admission, he developed sinus tachycardia and substernal, centralized, nonradiating chest pain. An electrocardiogram (ECG) showed sinus tachycardia without ST-T-wave abnormalities. His initial high-sensitivity troponin level was 23 ng/L, and it was 22 ng/L 2 hours later. Repeat CT of the head showed a stable intraventricular hemorrhage. He then had acute worsening of nausea with unchanged chest pain, thus prompting cardiology consultation. Physical examination was notable for tachycardia, regular rhythm, tachypnea, and a firm, distended, but nontender abdomen. Pulmonary and neurologic examinations were unremarkable. The chest pain was not positional. His blood pressure was 97/71 mm Hg and had been stable since admission.

A repeat ECG was obtained (**Figure 1A**). Subsequent coronary angiography was angiographically normal.

CT of the chest, abdomen, and pelvis with contrast enhancement showed a mid-to-distal small bowel obstruction (SBO) and gastric distention (**Figure 1B**). A nasogastric tube was placed, and 4.5 L of bilious material was evacuated, with immediate symptom resolution. Follow-up CT of the chest and ECG are shown in **Figures 1C and 1D**, respectively. A transthoracic echocardiogram showed normal cardiac structure and function.

What was likely the cause of the ECG findings in **Figure 1A**?

A) Pericarditis
B) Type 2 myocardial infarction
C) Superior translocation of the heart
D) Increased intracranial pressure

From the Gill Heart & Vascular Institute, University of Kentucky, Lexington, Kentucky, USA.
The authors attest they are in compliance with human studies committees and animal welfare regulations of the authors' institutions and Food and Drug Administration guidelines, including patient consent where appropriate. For more information, visit the Author Center.

Manuscript received June 29, 2021; revised manuscript received September 20, 2021, accepted September 23, 2021.

ISSN 2666-0849 https://doi.org/10.1016/j.jaccas.2021.09.010

JACC: CASE REPORTS, VOL. 3, NO. 16, 2021
NOVEMBER 17, 2021:1727–1729

ABBREVIATIONS AND ACRONYMS

CT = computed tomography

ECG = electrocardiogram

SBO = small bowel obstruction

The answer is C, superior translocation of the heart. Figure 1A shows ST-segment elevation in leads II, III, and aVF and reciprocal ST-segment depression in leads I and aVL, findings concerning for inferior wall type 1 myocardial infarction. However, coronary angiography findings were normal.

The ST-segment changes were likely the result of superior translocation of the heart from SBO-induced gastric distention that shifted the mean axis of depolarization relative to traditionally placed ECG leads. Figure 1B shows a superiorly translocated heart, which returned to a normal position

FIGURE 1 ECG and CT Findings

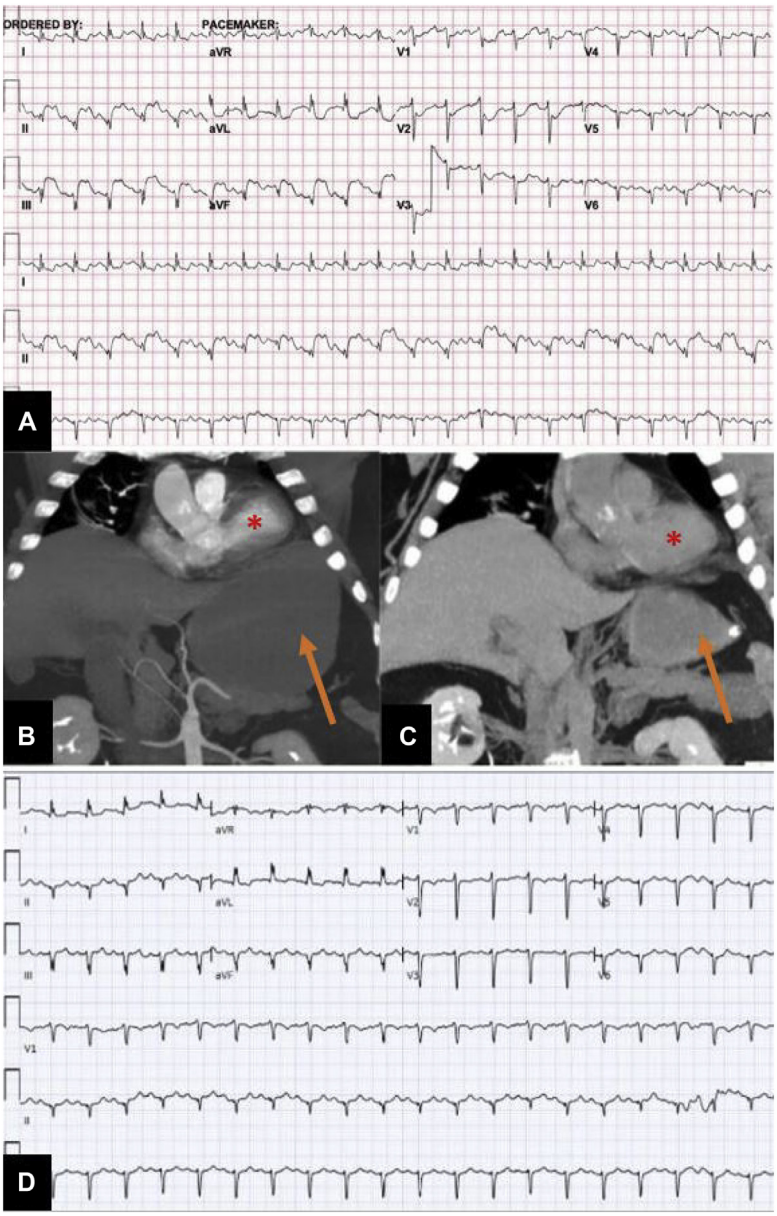

(A) Electrocardiogram (ECG) during acute worsening of nausea with persistent chest pain. **(B)** Chest computed tomography (CT)with contrast enhancement: anteroposterior view showing the heart **(asterisk)** and stomach **(arrow). (C)** Computed tomography of the abdomen and pelvis without contrast enhancement following gastric decompression showing the heart **(asterisk)** and stomach **(arrow). (D)** Electrocardiogram immediately after gastric decompression.

following gastric decompression (**Figure 1C**). Associated immediate resolution of ECG changes (**Figure 1D**) suggests that the SBO-induced gastric distention was the cause of the changes. SBO causing ST-segment elevation has been described in a small number of case reports (1-3). In some cases, inferior wall ischemia from extrinsic compression of the right coronary artery has been the proposed mechanism. This was less likely in our patient with normal coronary angiography and mild myocardial injury.

According to the Fourth Universal Definition of Myocardial Infarction, the diagnosis of type 2 myocardial infarction requires a rise and/or fall in troponin. Because there was no significant change in troponin in our patient, answer option B in the foregoing multiple-choice question is incorrect.

Pericarditis (answer option A in the multiple-choice question) is unlikely given the regionality in the ST-segment elevation and the nonpositional nature of the patient's chest pain.

ST-segment changes in intracerebral hemorrhage are thought to be the result of sustained sympathetic stimulation and a dysfunctional autonomic nervous system. Although this patient had risk factors for increased intracranial pressure (answer option D in the multiple-choice question), repeat cranial imaging was unchanged.

FUNDING SUPPORT AND AUTHOR DISCLOSURES

The authors have reported that they have no relationships relevant to the contents of this paper to disclose.

ADDRESS FOR CORRESPONDENCE: Dr Ranjan Banerjee, Gill Heart & Vascular Institute, University of Kentucky, Charles T. Wethington Building, Room 326, 900 South Limestone Street, Lexington, Kentucky 40536-0200, USA. E-mail: ranjan.banerjee@uky.edu.

REFERENCES

1. Parikh M, Amor MM, Verma I, et al. Small bowel obstruction masquerading as acute ST elevation myocardial infarction. *Case Rep Cardiol*. 2015;2015:685039.

2. Patel K, Chang N, Shulik O, et al. Small bowel obstruction mimicking acute ST elevation myocardial infarction. *Case Rep Surg*. 2015;2015:739147.

3. Siddique O, Rasla S, Clark S, et al. A case of ileus and ST segment elevation. *R I Med J*. 2013;99(11):44-46.

KEY WORDS angina, coronary angiography, extrinsic compression, small bowel obstruction, translocation