

University of Kentucky

UKnowledge

Radiation Medicine Faculty Publications

Radiation Medicine

1-26-2021

Radiation-Induced Oral Mucositis Hamster Model Using a Linear Accelerator Enhances Clinical Relevance of Preclinical Studies for Treatment Strategy Investigation

Carolyn T. Jordan
University of Kentucky


Emily M. Bradford
University of Kentucky, emily.bradford@uky.edu

Dennis C. Cheek
University of Kentucky, dennis.cheek@uky.edu

Mahesh R. Kudrimoti
University of Kentucky, mkudr0@email.uky.edu

Craig S. Miller
University of Kentucky, craig.miller@uky.edu

Follow this and additional works at: https://uknowledge.uky.edu/radmed_facpub

 *next page for additional authors*
Part of the [Chemical Engineering Commons](#), and the [Radiology Commons](#)

[Right click to open a feedback form in a new tab to let us know how this document benefits you.](#)

Repository Citation

Jordan, Carolyn T.; Bradford, Emily M.; Cheek, Dennis C.; Kudrimoti, Mahesh R.; Miller, Craig S.; Smith, Molly H.; Hilt, J. Zach; and Dziubla, Thomas D., "Radiation-Induced Oral Mucositis Hamster Model Using a Linear Accelerator Enhances Clinical Relevance of Preclinical Studies for Treatment Strategy Investigation" (2021). *Radiation Medicine Faculty Publications*. 26.
https://uknowledge.uky.edu/radmed_facpub/26

This Article is brought to you for free and open access by the Radiation Medicine at UKnowledge. It has been accepted for inclusion in Radiation Medicine Faculty Publications by an authorized administrator of UKnowledge. For more information, please contact UKnowledge@lsv.uky.edu.

Radiation-Induced Oral Mucositis Hamster Model Using a Linear Accelerator Enhances Clinical Relevance of Preclinical Studies for Treatment Strategy Investigation

Digital Object Identifier (DOI)

<https://doi.org/10.1002/ame2.12148>

Notes/Citation Information

Published in *Animal Models and Experimental Medicine*, v. 4, issue 1.

© 2021 The Authors

This is an open access article under the terms of the [Creative Commons Attribution-NonCommercial-NoDerivs](#) License, which permits use and distribution in any medium, provided the original work is properly cited, the use is non-commercial and no modifications or adaptations are made.

Authors

Carolyn T. Jordan, Emily M. Bradford, Dennis C. Cheek, Mahesh R. Kudrimoti, Craig S. Miller, Molly H. Smith, J. Zach Hilt, and Thomas D. Dziubla



Radiation-induced oral mucositis hamster model using a linear accelerator enhances clinical relevance of preclinical studies for treatment strategy investigation

Carolyn T. Jordan¹ | Emily M. Bradford² | Dennis C. Cheek³ | Mahesh Kudrimoti³ | Craig S. Miller⁴ | Molly H. Smith⁵ | J. Zach Hilt¹ | Thomas D. Dziubla¹

¹Department of Chemical and Materials Engineering, University of Kentucky, Lexington, KY, USA

²Department of Internal Medicine, University of Kentucky, Lexington, KY, USA

³Department of Radiation Medicine, University of Kentucky, Lexington, KY, USA

⁴Department of Oral Health Practice, University of Kentucky, Lexington, KY, USA

⁵Department of Oral and Maxillofacial Pathology, University of Kentucky, Lexington, KY, USA

Correspondence

Thomas D. Dziubla, 177 F. Paul Anderson Tower, Department of Chemical and Materials Engineering, University of Kentucky, Lexington, KY 40506, USA.
Email: Thomas.dziubla@uky.edu

Funding information

National Institute of Dental and Craniofacial Research, Grant/Award Number: R44DE023523

Abstract

Translational animal models for oral mucositis (OM) are necessary to simulate and assess the bioclinical effects and response in humans. These models should simulate high levels of radiation exposure that leads to oxidative stress and inflammatory-initiated tissue changes. Hamster models have been extensively studied to observe pathological effects of radiation exposure and help in the development of effective treatments. To successfully evaluate the potential for treatment regimens with consistency and relevance, a radiation-induced OM hamster model was developed using a clinical linear accelerator utilized by cancer patients daily. The dose exposure to the isolated, everted cheek pouch of a hamster, as well as the progression of injury, pro-inflammatory marker, histological, and elasticity analyses of the buccal pouch were conducted to verify replicability and reproducibility of the injury model. The findings from this model demonstrated its ability to consistently induce injury and resolution over 28 days using an acute dose of 60 Gy. This model was developed to enhance clinical relevance when evaluating potential efficacious treatments and can now be utilized in efficacy studies to better evaluate developed therapeutics in a preclinical model that is easy to translate to clinical studies..

KEYWORDS

animal models, radiotherapy, stomatitis

1 | INTRODUCTION

Oral mucositis (OM) affects a significant number of head and neck cancer patients receiving high doses of radiation or chemotherapy.^{1,2} It is a debilitating side effect that damages healthy epithelial tissue in the oral cavity and can result in severe ulcers. High dose radiotherapy often damages tissue via oxidative stress (OS), where the

antioxidant-free radical concentration becomes imbalanced. High-energy radiation may directly damage DNA or indirectly induce hydroxyl radical formation. The initiation of free radical generation triggers secondary messenger and signaling cascades that induce cell damage and apoptosis.³ Downstream, pro-inflammatory cytokines infiltrate the submucosa and amplify injury.⁴ This may lead to destruction of the mucosal epithelium and superficial or transmural

This is an open access article under the terms of the Creative Commons Attribution-NonCommercial-NoDerivs License, which permits use and distribution in any medium, provided the original work is properly cited, the use is non-commercial and no modifications or adaptations are made.

© 2021 The Authors. *Animal Models and Experimental Medicine* published by John Wiley & Sons Australia, Ltd on behalf of The Chinese Association for Laboratory Animal Sciences

ulceration. Unfortunately, OM does not have effective treatments, and costs can be measured financially as well as by delay in cancer therapy.

Animal models build upon *in vitro* studies and play a critical role in preclinical studies that serve as a translational pathway for drug discovery. Hamsters have been used extensively to study the pathogenesis and inflammatory processes involved in OM.⁵⁻¹¹ The similar characteristics of the hamster and human oral cavity, that is, similar onset of OM, bacterial flora and blood cell count contribute to its appeal.^{9,12} In prior investigations, oral ulcers in hamsters have been induced on everted, localized cheek pouches, and evaluated for onset, peak injury, and resolution of injury up to 28 days using sources such as a 250-kV potential (1-15 mA) source hardened with Cu or Al-filtration system to deliver 40 Gy,^{5,7,9} megavoltage through cobalt-60,¹⁰ or even induction through chemotherapeutic administration of 5-fluorouracil and artificial irritation by scratching the mucosa.¹² While these models are all effective in inducing mucositis, variation in the source, as well as artificial injury, can create varied injury making the findings difficult to translate into clinical studies.

In this communication, we present a precise, effective method to induce localized OM using a Truebeam linear accelerator in golden Syrian hamsters. This same instrument is used to treat thousands of cancer patients each day around the world. The use of a clinical instrument strengthens the translational impact of this model. The aim of this study was to determine the dose necessary to achieve injury and resolution within a 28-day window and provide end point analyses of pro-inflammatory marker levels, histological analysis, and elasticity of the hamster pouch.

2 | MATERIALS AND METHODS

2.1 | Animals

Four to six-week-old female and male golden Syrian hamsters with starting weights between 90 and 110 g were used for the radiation-induced OM model development (Envigo, Haslett, MI). Animals were housed individually, with environmental enrichment provided throughout the duration of the study. Standard rodent chow pellets (Envigo), non-fruit/vegetable food enrichment, and water were available *ad libitum*. All protocols were approved by the University of Kentucky Institutional Animal Care and Use Committee.

2.2 | Anesthesia

Prior to radiation, male hamsters were given 100 mg/kg ketamine (Henry Schein, Dublin, Ohio) in combination with 10 mg/kg xylazine (AnaSed, Sigma-Aldrich, St. Louis, MO intraperitoneally (IP), whereas females received 10% more ketamine and xylazine to maintain anesthesia for the duration of exposure. On average, hamsters reached an appropriate plane of anesthesia (even breathing, lack of pedal, and corneal reflex) in 5-10 minutes and this was sustained for

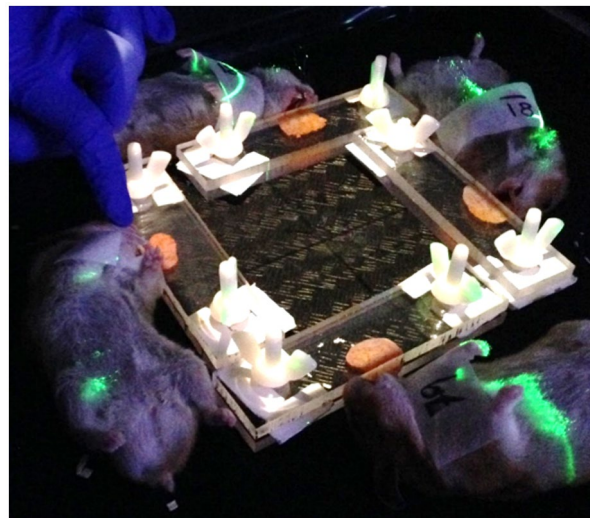


FIGURE 1 Hamster pouches everted and isolated by acrylic clamps designed for localized exposure to the field using the LINAC

45 minutes. An additional dose of ketamine only (30 mg/kg) was given 10 minutes following the initial dose if hamsters were not sufficiently anesthetized. Ophthalmic lubrication (Puralube, Dechra Veterinary Products, Overland Park, KS) was used to protect the eyes. Following irradiation, hamsters were placed on a heating pad and allowed to recover. Hamsters that were not ambulatory 30 minutes after anesthesia received 0.2 mg/kg atipamezole (Antisedan; Zoetis, Parsippany, NJ) IP to reverse the xylazine. Doses higher than 0.2 mg/kg caused discernible agitation with no improvement in recovery time.

2.3 | Dose-dependent radiation

A pilot study was performed to determine the optimal radiation dose to achieve progression and resolution of OM over a 28-day period. Hamsters were randomly divided into three groups and subjected to 20 ($n = 2$), 40 ($n = 4$), or 60 Gy ($n = 4$) using the 6-MV photon beam from a Varian Truebeam linear accelerator. Once anesthetized, the left cheek pouch of each hamster was extracted outside of the oral cavity (inverted) using blunt forceps and held in place using an acrylic clamp with a 1-mm spacer to inhibit constriction of blood flow (Figure 1). Water equivalent bolus was placed on top of the acrylic clamp, so the depth of the tissue was at the maximum depth dose (1.5 cm) for the 6 MV beam. High-energy 6MV x-rays were delivered locally to the everted pouch in 15×15 cm field, exposing the pouches for a total delivery 20, 40, and 60 Gy as a one-time dose (from 3 to 10 minutes). The three different doses of radiation were compared by daily observation and scored using an OM rubric (Table 1) over 28 days. Based on these limited pilot data, 60 Gy generated both sufficient injury and resolution over the 28-day time course and was used for all further studies (see Results). Combined with subsequent studies, a total of 22 hamsters ($n = 11$ male and

TABLE 1 Modified rubric based on Sonis et al. to evaluate progression of observational injury of the duration of the study

| Score | Description |
|-------|--|
| 0 | Pouch completely healthy. No erosion or vasodilation. |
| 1 | Erythema. Slight fibrosis between days 19 and 28. |
| 2 | Severe erythema, vasodilation, and superficial erosion. Fibrosis present between days 19 and 28. |
| 3 | Formation of ulcer, plaque covered ulcer, exophytic mass, or fibrotic tissue (in days 19-28 only) in one or more places, but not affecting more than 25% of the surface area of the pouch. Severe erythema and vasodilation. |
| 4 | Cumulative ulcer formation, plaque covered ulcer, exophytic mass, or fibrotic tissue (in days 19-28 only) in ~50% of pouch surface area. |
| 5 | Complete ulceration, plaque formation, exophytic mass, or fibrotic tissue (in day 19-28 only) covering the entire pouch and/or unable to extract. |

n = 11 female) over 5 independent rounds of 60 Gy acute radiation were evaluated.

2.4 | Evaluation of the progression of injury

Hamsters were evaluated daily by taking the weight and scoring the everted cheek pouch for OM based on a six-point system developed by Sonis et al with modification to the scale due to the presence of fibrotic tissue during the resolution period found in Table 1.⁷ Targeted points of interest were (a) the day in which erythema was present, (b) the day in which peak injury occurred, and (c) the day injury was resolved or the 28th day of the study, whichever occurred first.

To evert the cheek pouches for evaluation, hamsters were anesthetized with 5% isoflurane/O₂ in an induction chamber and maintained at 2.5% isoflurane/O₂ delivered through a nose cone. Forceps were gently inserted into the oral cavity and the pouch was everted by clasp the base of the pouch and inverting it outside of the mouth for observation. Evaluation of the top and bottom of the pouch was completed while stretched into a triangular configuration. Pictures were taken using an Olympus Tough TG-5 camera in the microscope setting for close-up imaging with a ruler present in each picture. The entire procedure took less than 2 minutes per hamster. The cheek pouches were scored blindly at the time of evaluation by two trained individuals. To maintain pain management and care of the animals, hamsters that had a score of 3 were administered 0.1 mg/kg buprenorphine IP once daily, and scores 4 and greater received 0.1 mg/kg buprenorphine IP twice daily. Hamsters that lost weight over 2 days were given a hydrogel water cup (ClearH₂O, Portland, ME) to help reduce dehydration. Loss of 20% body weight was considered a humane endpoint, which occurred in less than 0.5% of the sample size (n = 22).

2.5 | Quantitative elasticity measurements

The widest part of the hamster pouch, the hypotenuse of the extracted pouch, was quantitatively evaluated at three time points of interest: baseline (day 0), peak injury (day 18), and end point (day 28)

to compare elasticity throughout the study (n = 22). Widths of the extracted pouches were normalized to the starting values to determine change in elasticity.

2.6 | Tissue collection for H&E and OS markers

On day 28, hamsters were euthanized using isoflurane overdose and bilateral thoracotomy. The left and right cheek pouches were excised, and each cheek pouch was cut in half. One half was pinned and fixed in 10% neutral buffered formalin (NBF), and the other half was snap frozen in liquid nitrogen and stored at -80°C for tissue processing for ELISAs of various oxidative stress and pro-inflammatory biomarkers including protein carbonyl, 4-HNE, TNF- α , IL-10, and IL-6, respectively.

Tissues that were fixed in 10% NBF overnight were then processed through paraffin, sectioned at 5 μ m, and stained with hematoxylin and eosin (H&E). Slides were imaged on an Olympus BX41 microscope with a mounted Olympus DP71 camera.

For biomarker analysis, the frozen pouches were weighed and a target tissue concentration of 200 mg/mL in a 1x protease cocktail inhibitor was used to extract protein content from the connective tissue using a glass tissue homogenizer. A bicinchoninic acid assay (BCA) was used to determine protein levels. Enzyme-linked immunosorbent assays (ELISA) were performed according to the manufacturer's protocol. These included TNF- α , 4-HNE, protein carbonyl, IL-10, and IL-6 (MyBioSource, San Diego, CA). Each marker is reported in molar concentration per milligram protein within the linearity of the assay.

2.7 | Statistical analysis

For all figures, error bars represent standard error of the mean (SEM). The elasticity measurements were analyzed using a one-way ANOVA to evaluate significance between the start, peak, and end point analysis ($P < .05$) and the inflammatory marker analysis utilized the Dunnett's test for uneven sample size populations (basal level [n = 5] vs 60 Gy exposure [n = 22]).

3 | RESULTS

3.1 | Dose-dependent radiation

Cheek pouches were evaluated two times at baseline, 24 hours apart, and then irradiated. (Figure 2A). To immobilize hamsters during localized dosing of radiation, anesthetic was required. Female hamsters had a higher tolerance for anesthesia, and it was necessary to use 10% more ketamine and xylazine to induce and maintain the anesthetic plane. To evaluate injury progression, photo documentation

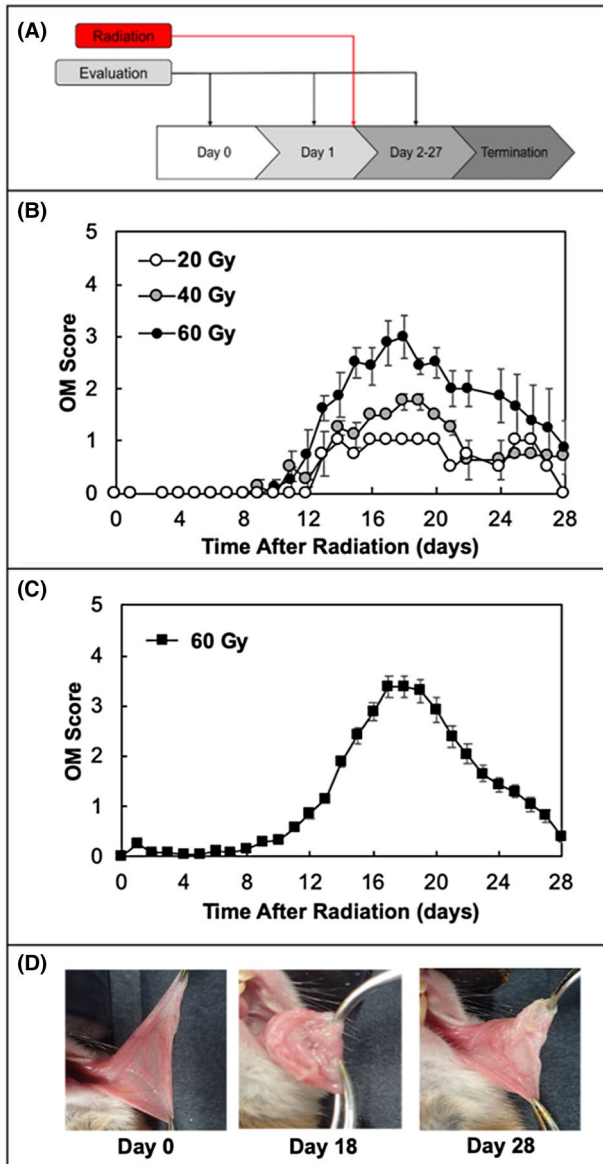


FIGURE 2 Method development of the RIOM using the LINAC. Experimental setup of the injury model (A), Dose-dependent pilot study to evaluate injury at 20 (n = 2), 40, and 60 Gy (n = 4 for 40 and 60 Gy) (B), progression and evaluation of injury of a positive control in a large-scale animal study (n = 22) (C), and cheek pouch images of injury on days 0, 18, and 28 (D). Error bars depict Mean \pm SEM

was collected on days 2-27, and the pouch was blindly scored using the modified rubric in Table 1. Onset of injury was similar in all three radiation groups, with tissue irritation observed initially between days 8 and 12 after radiation. The onset of slight erythema was observed at day 14 for the 20 Gy exposure group and by day 12 in the 40 Gy and 60 Gy groups (unirradiated control hamsters did not develop erythema or ulceration). Peak damage was significantly different among the three groups. Hamsters exposed to localized exposure of 20 Gy never had an OM score of greater than 1.0. The groups exposed to 40 Gy had injury progress from erythema to slight mucosal sloughing; however, they resolved completely back to baseline after 22 days without formation of ulcers. At 60 Gy, the entire mucosal lining was completely disrupted from the pouch and ulcers formed within the bed of the cheek in all hamsters. The peak day of injury was day 18, at which time the pouches were swollen, challenging to evert, and over 50% of the pouch surface was ulcerated (Figure 2D). After peak injury, pouches scoring 1 quickly resolved by day 24. The acute dose evaluation was repeated with 40 and 60 Gy exposure groups (ie, a total of four hamsters in each group) to be able to calculate the average and SEM (Figure 2B). The replicability and consistency of the 60 Gy dose was further evaluated with a large sample size (n = 22) to show precision of model and injury-mediated ulceration (Figure 2C) with an overall survival rate of 100% throughout the entirety of the study.

3.2 | Elasticity of pouch

Hamsters exposed to 60 Gy (n = 22) demonstrated pouch elasticity changes. The pouch elasticity appears to change significantly ($P < .05$) between day 0 (start) and day 18 (peak injury) and start and end point analysis, where no change in elasticity appears to occur after peak injury. The normalized pouches at the start of the experiment were 1.0 ± 0.03 , but as injury onsets, the normalized width of the pouch reduces to 0.83 ± 0.03 at day 18 consistent with the inflammatory response and formation of ulcers. It is interesting to note that the ulcers completely heal by the end point analysis (day 28), yet the emergence of fibrotic tissue occurs and inhibits the pouch from regaining baseline elasticity (Figure 3A).

3.3 | Histopathology

Hematoxylin and eosin staining was conducted on paraffin-embedded tissue sections to observe end point analysis of pouch morphology in the hamsters that received 60 Gy (n = 22). Irradiated pouches were directly compared to baseline pouches (Figure 3B). At baseline, healthy intact epithelium was seen (black arrow) with normal muscle and connective tissue. In the irradiated pouch (day 28), neutrophilic and lymphocytic infiltration was observed in the submucosa (densely populated area with nuclei) and destruction of the epithelium was still evident. Plump fibroblasts were seen throughout the sample as commonly seen in human patients that have been exposed

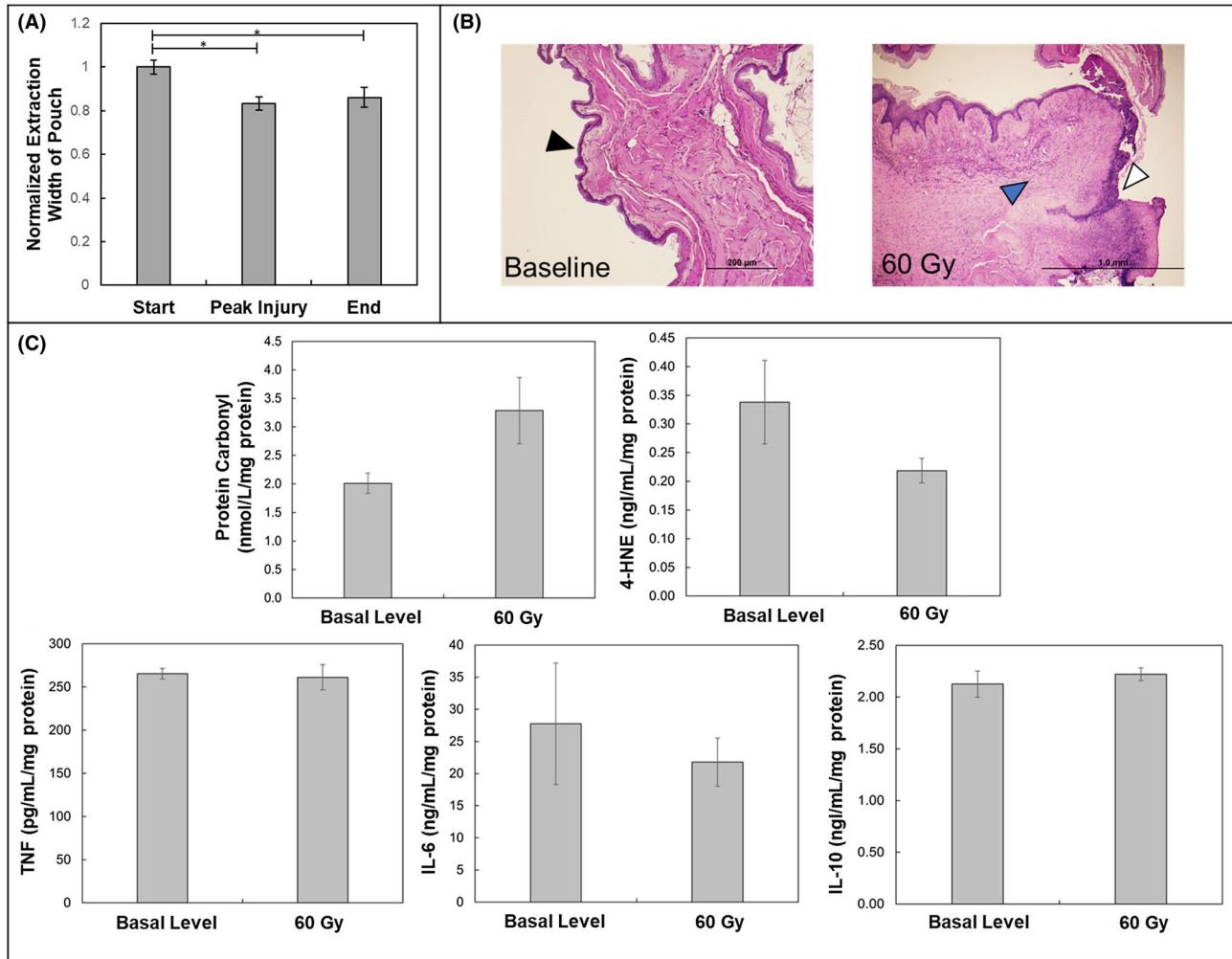


FIGURE 3 End point analysis at day 28. Normalized quantitative values of extraction widths of irradiated cheek pouches at day 0 (start), day 18 (peak injury), and end (day 27) (A). Hematoxylin and eosin staining of a baseline cheek pouch compared to an irradiated cheek pouch at day 28. Black arrow represents intact/healthy epithelium, blue arrow represents inflammatory infiltrate, and white arrow represents disrupted epithelium. Representative images are shown at 10x magnification. (B). Oxidative and inflammatory biomarker analysis at day 28 of 60 Gy exposure compared to basal levels (C). (n = 22, Mean \pm SEM) *represents significance ($P < .05$)

to radiotherapy.¹³ The formation of dense fibrosis also was observed (blue arrow). These characteristics of fibrosis and epithelial sloughing align with the average score of 1.5 through the irradiated pouch population.

3.4 | ELISA analysis of pro-inflammatory and OS markers

To determine end point levels of pro-inflammatory and oxidative stress biomarker levels, TNF- α , IL-6, IL-10, protein carbonyl, and 4-HNE were evaluated in the pouches that were exposed to 60 Gy (n = 22) using ELISAs and directly compared to nonirradiated pouches (n = 5) (Figure 3C). TNF- α , IL-10, and IL-6 did not have a significant difference at day 28 when compared to basal levels; however, the protein carbonyl levels were elevated from 2.01 ± 0.18 nmol/L/mg protein to 3.29 ± 0.77 nmol/L/mg after radiation exposure compared

to basal levels in unirradiated pouches. As protein carbonyl formation is a type of protein oxidation specific to reactive oxygen species, the elevated amount found in the exposed tissue supports the hypothesis of oxidative damage. Furthermore, 4-HNE levels decreased from 0.338 ± 0.03 nmol/L/mg protein to 0.218 ± 0.07 nmol/L/mg protein in the exposure group compared to nonirradiated pouches. However, this change in marker level cannot be claimed as significant, as the Dunnett's test was used to analyze these populations of uneven sample size (n = 5 vs n = 22).

4 | DISCUSSION

Oral mucositis is a debilitating adverse effect of radiotherapy that is in need for an effective treatment. Animal models that closely mimic the human experience are also needed. In this study, doses were evaluated to achieve injury and resolution within a 28-day

experimental evaluation using a linear accelerator and provide end point analyses of pro-inflammatory markers, histological analysis, and elasticity of the hamster pouch. The linear accelerator radiation to the hamster cheek pouch resulted in injury that approximated mucositis, with minimal variation and 100% survivability. At 40 Gy, linear accelerator radiation induced epithelial sloughing but no greater injury. In contrast, 60 Gy exposure induced ulcers that covered up to 50% of the exposed pouch, and apparent fibrosis after 28 days of evaluation. Peak injury, as determined using the OM rubric, occurred at day 18 and resolution of injury occurred by day 28.

An interesting finding was the modification to anesthetic dosages when anesthetizing females vs males for the purpose of immobilization during radiation exposure. A 10% increase in ketamine and xylazine to anesthetize female hamsters for the appropriate amount of time. While this has not been extensively studied in hamsters, there has been similar observation in mice, resulting in small therapeutic windows of anesthesia for female rodents.¹⁴

From our results, observational recognition of injury using photo documentation with scoring guidelines in the OM rubric in Table 1 and elasticity measurements are both valuable ways to determine erythema and sloughing as well as morphological changes during injury onset and progression throughout the study. These are helpful intermediate evaluations to be able to conduct throughout the entire duration of the study to understand impact of injury. End point analysis (day 28) was conducted to utilize pro-inflammatory marker analysis as well as H&E staining to understand radiation exposure effects to the tissue; however, the pro-inflammatory markers that were analyzed are hypothesized to be elevated specifically during the onset of injury.^{15,16} When analyzed at a later time point (ie, day 28), the markers resolve below significantly different levels when compared to basal levels, which could be explained by resolution of gross injury. This hypothesis could be tested in future studies, specific to efficacy, by collecting tissue from euthanized animals during earlier time points and analyzing them for pro-inflammatory markers during onset of injury. Additionally, evidence also suggested that elevated oxidative stress, as determined by protein carbonyl formation, correlated with enhanced injury in this model. While HNE production was not elevated (as would be expected in oxidative stress), HNE is a transient marker and not likely to persist as long as oxidized proteins may in the tissue bed. Further work would need to be conducted to determine if changes in extracellular matrix proteins (which may persist for longer periods of time) account for these elevated levels in protein carbonyl.

5 | CONCLUSIONS

Here, we show that use of the linear accelerator provides a relevance to human injury model during radiotherapy. Observational evaluations, elasticity measurements, and biochemical findings of the cheek pouch are great characterization techniques to utilize for efficacy studies using the linear accelerator as source of acute injury. They can all be readily used for evaluating a multitude of different therapeutic methods of administration, such as topical, intravenous,

and intraperitoneal, for the treatment of OM. Upon further validation, this model provides the opportunity to evaluate efficacy and effectiveness of developed and developing therapeutics to one day provide a cure for OM in cancer patients.

ACKNOWLEDGMENTS

This work was completed under support through NIH SBIR Phase II Award R44DE023523. The authors acknowledge Kelley Wiegman, Dustin Savage, and Brock Howerton for their assistance in the processing procedures for the ELISA assays conducted by Jennifer Moylan at the Center for Clinical and Translational Sciences. Furthermore, the authors acknowledge Dr. Kryscio for providing the statistical analysis on the inflammatory marker level studies and would also like to acknowledge the Markey Cancer Center and the generosity of using their TrueBeam Linear Accelerator.

CONFLICT OF INTEREST

The authors of this work have equity, ownership in, and serve as advisors for Bluegrass Advanced Materials, LLC which is currently developing products related to the research being reported. The terms of this arrangement have been reviewed and approved by the University of Kentucky in accordance with its responsible conduct of research policies.

ORCID

Carolyn T. Jordan  <https://orcid.org/0000-0002-1243-0038>

REFERENCES

- Berger K, Schopohl D, Bollig A, et al. Burden of oral mucositis: a systematic review and implications for future research. *Oncol Res Treat.* 2018;41(6):399-405.
- Lalla RV, Brennan MT, Gordon SM, Sonis ST, Rosenthal DI, Keefe DM. Oral mucositis due to high-dose chemotherapy and/or head and neck radiation therapy. *JNCI Monographs.* 2019;2019(53):lgz011.
- Krishnatry R, Nachankar A, Gupta T, Agarwal JP. Radiation mucositis: a short review. *Int J Head Neck Surg.* 2011;2:37-43.
- Kwon Y. Mechanism-based management for mucositis: option for treating side effects without compromising the efficacy of cancer therapy. *OncoTargets Ther.* 2016;9:2007-2016.
- Watanabe S, Suemaru K, Nakanishi M, et al. Assessment of the hamster cheek pouch as a model for radiation-induced oral mucositis, and evaluation of the protective effects of keratinocyte growth factor using this model. *Int J Radiat Biol.* 2014;90(10):884-891.
- Koohi-Hosseiniabadi O, Andisheh-Tadmir A, Bahadori P, Sepehrimanesh M, Mardani M, Tanideh N. Comparison of the therapeutic effects of the dietary and topical forms of *Zizyphus jujuba* extract on oral mucositis induced by 5-fluorouracil: a golden hamster model. *J Clin Exp Dent.* 2015;7:e304-e309.
- Sonis S, Peterson R, Edwards L, et al. Defining mechanisms of action of interleukin-11 on the progression of radiation-induced oral mucositis in hamsters. *Oral Oncol.* 2000;36(4):373-381.
- Lima V, Brito GAC, Cunha FQ, et al. Effects of the tumour necrosis factor- α inhibitors pentoxifylline and thalidomide in short-term experimental oral mucositis in hamsters. *Eur J Oral Sci.* 2005;113(3):210-217.
- Murphy CK, Fey EG, Watkins BA, Wong V, Rothstein D, Sonis ST. Efficacy of superoxide dismutase mimetic M40403 in attenuating radiation-induced oral mucositis in hamsters. *Clin Cancer Res.* 2008;14(13):4292-4297.



10. Bastos Moura JF, Mota JM, Leite CAV, et al. A novel model of megavoltage radiation-induced oral mucositis in hamsters: role of inflammatory cytokines and nitric oxide. *Int J Radiat Biol.* 2015;91:1-10.
11. Ara G, Watkins BA, Zhong H, et al. Velafermin (rhFGF-20) reduces the severity and duration of hamster cheek pouch mucositis induced by fractionated radiation. *Int J Radiat Biol.* 2008;84(5):401-412.
12. Sá O, Lopes N, Alves M, Caran E. Effects of glycine on collagen, PDGF, and EGF expression in model of oral mucositis. *Nutrients.* 2018;10(10):1485.
13. Gehrke T, Scherzad A, Hackenberg S, et al. Long-term changes in the properties of skin-derived fibroblasts following irradiation of the head and neck. *Oncol Lett.* 2017;14(3):3780-3786.
14. Levin-Arama M, Abraham L, Waner T, et al. Subcutaneous compared with intraperitoneal ketamine xylazine for anesthesia of mice. *J Am Assoc Lab Anim Sci.* 2016;55(6):794-800.
15. Sonis ST. Oral mucositis. *Anticancer Drugs.* 2011;22(7):607-612.
16. Scully C, Epstein J, Sonis S. Oral mucositis: a challenging complication of radiotherapy, chemotherapy, and radiochemotherapy: part 1, pathogenesis and prophylaxis of mucositis. *Head Neck.* 2003;25(12):1057-1070.

How to cite this article: Jordan CT, Bradford EM, Cheek DC, et al. Radiation-induced oral mucositis hamster model using a linear accelerator enhances clinical relevance of preclinical studies for treatment strategy investigation. *Anim Models Exp Med.* 2021;4:47-53. <https://doi.org/10.1002/ame2.12148>