



6-2015

# An Ex Vivo Approach to Complex Renal Artery Aneurysm Repair

Noah T. Scherrer

*University of Kentucky*, [noah.scherrer@uky.edu](mailto:noah.scherrer@uky.edu)

Roberto Gedaly

*University of Kentucky*, [roberto.gedaly@uky.edu](mailto:roberto.gedaly@uky.edu)

Ramakrishna Venkatesh

*University of Kentucky*

Michael A. Winkler

*University of Kentucky*, [michael.winkler@uky.edu](mailto:michael.winkler@uky.edu)

Eleftherios S. Xenos

*University of Kentucky*, [eleftherios.xenos@uky.edu](mailto:eleftherios.xenos@uky.edu)

**[Click here to let us know how access to this document benefits you.](#)**

Follow this and additional works at: [https://uknowledge.uky.edu/surgery\\_facpub](https://uknowledge.uky.edu/surgery_facpub)

 Part of the [Surgery Commons](#)

## Repository Citation

Scherrer, Noah T.; Gedaly, Roberto; Venkatesh, Ramakrishna; Winkler, Michael A.; and Xenos, Eleftherios S., "An Ex Vivo Approach to Complex Renal Artery Aneurysm Repair" (2015). *Surgery Faculty Publications*. 24.

[https://uknowledge.uky.edu/surgery\\_facpub/24](https://uknowledge.uky.edu/surgery_facpub/24)

This Article is brought to you for free and open access by the Surgery at UKnowledge. It has been accepted for inclusion in Surgery Faculty Publications by an authorized administrator of UKnowledge. For more information, please contact [UKnowledge@lsv.uky.edu](mailto:UKnowledge@lsv.uky.edu).

---

**An Ex Vivo Approach to Complex Renal Artery Aneurysm Repair**

**Notes/Citation Information**

Published in *Journal of Vascular Surgery Cases*, v. 1, no. 2, p. 165-167.

Copyright © 2015 The Authors. Published by Elsevier Inc. on behalf of the Society for Vascular Surgery.

This is an open access article under the CC BY-NC-ND license (<http://creativecommons.org/licenses/by-nc-nd/4.0/>).

**Digital Object Identifier (DOI)**

<http://dx.doi.org/10.1016/j.jvsc.2015.04.005>

# An ex vivo approach to complex renal artery aneurysm repair

Noah T. Scherrer, MD,<sup>a</sup> Roberto Gedaly, MD,<sup>b</sup> Ramakrishna Venkatesh, MD,<sup>c</sup> Michael A. Winkler, MD,<sup>d</sup> and Eleftherios S. Xenos, MD, PhD,<sup>a</sup> Lexington, Ky

Ex vivo repair technique for a complex renal artery aneurysm may have several advantages. Smaller incision size and use of minimally invasive techniques may decrease incisional morbidity and improve recovery time, especially in patients with a high body mass index. Improved visualization afforded by back-table methods may also be valuable when repair of aneurysms involving multiple branches is necessary. We report of a successful case of laparoscopic nephrectomy, followed by back-table aneurysmorrhaphy and autotransplant, in a patient with a renal artery aneurysm. (*J Vasc Surg Cases* 2015;1:165-7.)

Renal artery aneurysm (RAA) often presents a complex problem for both endovascular and open surgical repair. We report ex vivo aneurysmorrhaphy after a laparoscopic nephrectomy with autotransplantation. We obtained consent from the patient to publish this case report.

## CASE REPORT

A 66-year-old man was noted by his primary care doctor to be hypertensive, with a blood pressure of 206/110 mm Hg despite two maintenance medications (lisinopril and hydrochlorothiazide). Renal artery arterial duplex ultrasound imaging was concerning for a RAA. A computed tomography (CT) angiogram confirmed the presence of a 2.5-cm saccular bilobed aneurysm at the first branch of the main renal artery. Three-dimensional reconstructions are shown in Fig 1. A 1.5-cm RAA was demonstrated on the contralateral side, which was regular in appearance and without thrombus. Both renal arteries were free of stenosis.

Surgical repair of his complex RAA was sought due to the size as well as the saccular characteristics of the aneurysm. Ex vivo repair was planned. First, a laparoscopic nephrectomy was performed using three trocar sites and a periumbilical midline incision. Principles of donor nephrectomy were applied to preserve maximal length of the renal vessels and ureter. On the back table, the kidney was flushed with 4°C University of Wisconsin renal preservation solution.

Upon entering the aneurysm, clear differentiation between the normal artery and thinned aneurysmal wall was visualized. The

RAA was excised to a margin of nondiseased renal artery, and the arteriotomy was closed with a running Prolene (Ethicon, Somerville, NJ) suture. The back-table dissection of the RAA is shown in Fig 2.

The autotransplant was performed using an open right retroperitoneal external iliac artery exposure. Ureteral reconstruction was performed in concert with the transplant and urology team. Fig 3 shows the renal artery anastomosis to the right external iliac artery with the aneurysmorrhaphy suture line.

The overall operative time was 6 hours, with total ischemia time of 105 minutes and total warm ischemia time of 28 minutes, consisting of 3 minutes before cooling and 25 minutes during reimplantation. Blood loss for the procedure was ~250 mL.

The patient's postoperative stay was 5 days, and his course was uneventful. His serum creatinine peaked on postoperative day 1 at 1.37 mg/dL (from baseline 0.93 mg/dL) and trended back to normal levels by day 2. Duplex ultrasound imaging of the transplanted kidney on postoperative day 1 showed good flow in the renal artery and vein, with normal resistive indices. A nuclear medicine renal scan on postoperative day 1 showed only slightly decreased function in the transplanted kidney. No abnormal findings were noted in the pathologic report. Before discharge the patient was normotensive on the same hypertensive medication he was taking preoperatively.

The patient was readmitted 2 weeks after discharge for obstipation. A CT of the abdomen and pelvis revealed constipation. Full bowel function returned with just the cathartic effects of the oral contrast given for the CT scan, and the patient was discharged after 48 hours. At that time his renal function was normal. Results of a duplex ultrasound of the transplanted kidney were normal. The patient was seen in the clinic 4 weeks postoperatively and has had no further issues.

## DISCUSSION

RAA is a rare disease entity with little known about the natural history. There is some debate surrounding indication for repair of a RAA in an asymptomatic patient. Most agree that the threshold for operative intervention is between 2 and 4 cm<sup>1-3</sup>; however, other factors, such as age and comorbid conditions, may alter the threshold for surgical repair. An RAA in women of childbearing age

From the Section of Vascular Surgery, Department of Surgery,<sup>a</sup> Section of Abdominal Transplantation, Transplant Surgery Department,<sup>b</sup> Urology Department,<sup>c</sup> and Radiology Department,<sup>d</sup> University of Kentucky.

Author conflict of interest: none.

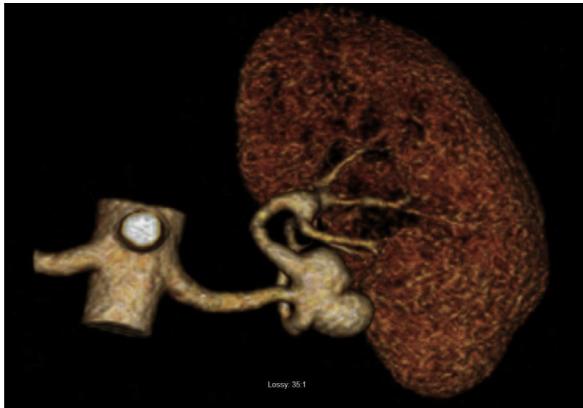Reprint requests: Noah T. Scherrer, MD, C216 AB Chandler Medical Center, 800 Rose St, Lexington, KY 40536 (e-mail: [scherrer.noah@gmail.com](mailto:scherrer.noah@gmail.com)).

The editors and reviewers of this article have no relevant financial relationships to disclose per the Journal policy that requires reviewers to decline review of any manuscript for which they may have a conflict of interest.

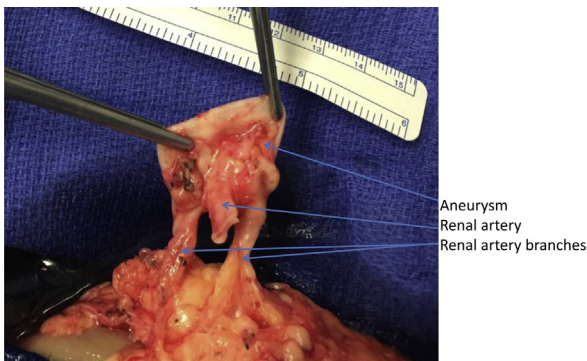
2352-667X

Copyright © 2015 The Authors. Published by Elsevier Inc. on behalf of the Society for Vascular Surgery. This is an open access article under the CC BY-NC-ND license (<http://creativecommons.org/licenses/by-nc-nd/4.0/>).

<http://dx.doi.org/10.1016/j.jvsc.2015.04.005>



**Fig 1.** Three-dimensional rendering of the left renal artery aneurysm (RAA).

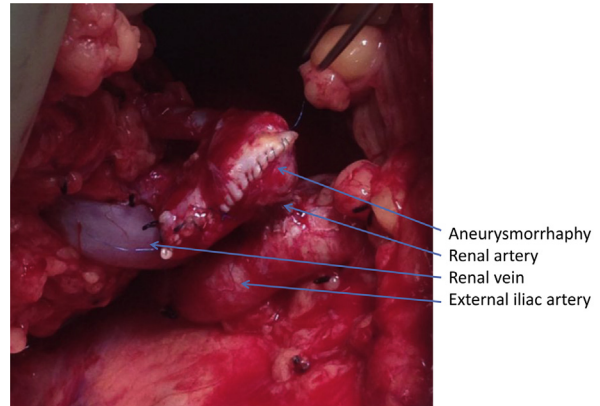


**Fig 2.** Back-table dissection of the left renal artery aneurysm (RAA).

should be repaired due to the increased risk of rupture and poor outcomes described with conservative management.<sup>4</sup>

Most RAAs are saccular and involve one or multiple branches.<sup>5,6</sup> Because of this, endovascular options are often limited, and open repair remains the mainstay for these complex cases. The complex nature of the repair can lead to prolonged warm ischemia time and nephron loss. If the warm ischemia time >30 minutes is expected, renal cooling should be performed.<sup>7</sup>

Multiple methods of renal cooling and preservation have been described, most of which involve controlling the renal artery, with or without complete vein control, and repairing the RAA with the ureter in place. This is most often performed through a subcostal incision. In patients with an increased body mass index, this can require a large incision, and in all patients can be associated with increased pain and morbidity in the postoperative course. Although this patient was not morbidly obese (body mass index of 30.1 kg/m<sup>2</sup>), back-table dissection also offered the advantage of enhanced visualization over an *in vivo* technique. In this case we were prepared to perform a complex, multibranch, reconstruction using a saphenous vein



**Fig 3.** Autotransplanted left kidney with vascular anastomosis to the right external iliac artery.

graft. For these reasons, this approach was deemed to be most appropriate for our patient.

The smaller incisions associated with the laparoscopic nephrectomy and autotransplant method may improve recovery time and have fewer complications. Laparoscopic donor nephrectomy with back-table repair is performed in the urologic community for excision of complex renal tumors as well as complex ureteral strictures. Although ureter reimplantation introduces a new set of postoperative risks, with a complication rate of 8.1% reported after ureter anastomosis,<sup>8</sup> this detriment may be offset by improved recovery times afforded by the smaller incisions associated with the laparoscopic nephrectomy and autotransplant method. By avoiding the large upper abdominal incision required for conventional open repair, respiratory complication can also be minimized, which may be an additional advantage in certain at-risk populations.

## CONCLUSIONS

We report the successful repair of a complex RAA using *ex vivo* technique, with no complications or sustained alteration in renal function. This finding is consistent with a case series that also describes preserved renal function in seven patients after use of this technique.<sup>9</sup> For properly selected patients with complex RAAs, laparoscopic nephrectomy with back-table reconstruction and autotransplant is a viable option.

## REFERENCES

1. Fry WF. Renal artery aneurysm. In: Ernst CB, Stanley JC, editors. *Current therapy in vascular surgery*. Philadelphia: BC Decker; 1987. p. 363.
2. Calligaro KD, Dougherty MJ. Chapter 148. Renovascular disease: aneurysms and arteriovenous fistulae. In: Cronenwett JL, Johnston W, editors. *Rutherford's vascular surgery*. 7th edition. Philadelphia: WB Saunders; 2010. p. 2329.
3. Van Way CW 3rd. Renal artery aneurysms and arteriovenous fistulae. In: Rutherford RB, editor. *Vascular surgery*. 4th edition. Philadelphia: WB Saunders; 1995. p. 1438.
4. Cohen JR, Shamash FS. Ruptured renal artery aneurysm during pregnancy. *J Vasc Surg* 1987;6:51-9.

5. Poutasse EF. Renal artery aneurysms: their natural history and surgery. *J Urol* 1966;95:297-306.
6. Henke PK, Cardneau JD, Welling TH, Upchurch GR, Wakefield TW, Jacobs LA, et al. Renal artery aneurysms: a 35-year clinical experience with 252 aneurysms in 168 patients. *Ann Surg* 2001;234:454-63.
7. Crutchley TA, Pearce JD, Craven TE, Edwards MS, Dean RH, Hansen JK. Branch renal artery repair with cold perfusion protection. *J Vasc Surg* 2007;46:405-12.
8. Santiago-Delpin EA, Gonzalez Z. Low incidence of urologic complications after renal transplantation. *Am J Surg* 1986;151:374-7.
9. Gallagher KA, Phelan MW, Stern T, Bartlett ST. Repair of complex renal artery aneurysms by laparoscopic nephrectomy with ex vivo repair and autotransplantation. *J Vasc Surg* 2008;48:1408-13.

Submitted Feb 2, 2015; accepted Apr 17, 2015.