University of Kentucky
UKnowledge

Center for Oral Health Research Faculty Publications | Oral Health Research

11-2018

Odontogenic Abscesses in Rhesus Macaques *(Macaca mulatta)* of Cayo Santiago

Hong Li
Capital Medical University, China

Wenjing Luo
Texas A&M University

Anna Feng
Marquette University

Michelle L. Tang
Georgia Institute of Technology

Terry B. Kensler
University of Puerto Rico Medical Sciences Campus

See next page for additional authors

Follow this and additional works at: https://uknowledge.uky.edu/cohr_facpub

Part of the Biological and Physical Anthropology Commons, and the Dentistry Commons

Right click to open a feedback form in a new tab to let us know how this document benefits you.

Repository Citation

Li, Hong; Luo, Wenjing; Feng, Anna; Tang, Michelle L.; Kensler, Terry B.; Maldonado, Elizabeth; Gonzalez, Octavio A.; Kessler, Matthew J.; Dechow, Paul C.; Ebersole, Jeffrey L.; and Wang, Qian, "Odontogenic Abscesses in Rhesus Macaques *(Macaca mulatta)* of Cayo Santiago" (2018). *Center for Oral Health Research Faculty Publications*. 21.
https://uknowledge.uky.edu/cohr_facpub/21

This Article is brought to you for free and open access by the Oral Health Research at UKnowledge. It has been accepted for inclusion in Center for Oral Health Research Faculty Publications by an authorized administrator of UKnowledge. For more information, please contact UKnowledge@lsv.uky.edu.

Odontogenic Abscesses in Rhesus Macaques *(Macaca mulatta)* of Cayo Santiago

Digital Object Identifier (DOI)
https://doi.org/10.1002/ajpa.23641

Notes/Citation Information
Published in *American Journal of Physical Anthropology,* v. 167, issue 3.

© 2018 Wiley Periodicals, Inc.

The copyright holder has granted the permission for posting the article here.

The document available for download is the authors' post-peer-review final draft of the article.

This is the peer reviewed version of the following article: Li, H., Luo, W., Feng, A., Tang, M. L., Kensler, T. B., Maldonado, E., Gonzalez, O. A., Kessler, M. J., Dechow, P. C., Ebersole, J. L., & Wang, Q. (2018). Odontogenic abscesses in rhesus macaques (*macaca mulatta*) of Cayo Santiago. *American Journal of Physical Anthropology*, *167*(3), 441-457, which has been published in final form at https://doi.org/10.1002/ajpa.23641.

This article may be used for non-commercial purposes in accordance with Wiley Terms and Conditions for Use of Self-Archived Versions.

Authors
Hong Li, Wenjing Luo, Anna Feng, Michelle L. Tang, Terry B. Kensler, Elizabeth Maldonado, Octavio A. Gonzalez, Matthew J. Kessler, Paul C. Dechow, Jeffrey L. Ebersole, and Qian Wang

This article is available at UKnowledge: https://uknowledge.uky.edu/cohr_facpub/21

Author Manuscript
Author Manuscript
Author Manuscript
Author Manuscript

HHS Public Access
Author manuscript
Am J Phys Anthropol. Author manuscript; available in PMC 2019 September 27.

Published in final edited form as:
Am J Phys Anthropol. 2018 November ; 167(3): 441–457. doi:10.1002/ajpa.23641.

Odontogenic Abscesses in Rhesus Macaques (*Macaca mulatta*) of Cayo Santiago

Hong Li[1], **Wenjing Luo**[2], **Anna Feng**[3], **Michelle L. Tang**[4], **Terry B. Kensler**[5], **Elizabeth Maldonado**[5], **Octavio A. Gonzalez**[6], **Matthew J. Kessler**[7], **Paul C. Dechow**[2], **Jeffrey L. Ebersole**[8], **Qian Wang**[2,*]

[1]Department of Endodontics, School of Stomatology, Capital Medical University, Beijing 100050, P.R. China

[2]Department of Biomedical Sciences, Texas A&M University Baylor College of Dentistry, Dallas, Texas

[3]Pre-dental Scholars Program, Marquette University, Milwaukee, Wisconsin

[4]Department of Chemistry and Biochemistry, Georgia Institute of Technology, Atlanta, Georgia

[5]Caribbean Primate Research Center, University of Puerto Rico Medical Sciences Campus, San Juan, Puerto Rico

[6]Center for Oral Health Research, College of Dentistry, University of Kentucky, Lexington, Kentucky

[7]Office of Laboratory Animal Resources, Robert C. Byrd Health Sciences Center, West Virginia University, Morgantown, West Virginia

[8]School of Dental Medicine, University of Nevada, Las Vegas, Nevada

Abstract

Objectives—Odontogenic abscesses are one of the most common dental diseases causing various maxillofacial skeletal lesions. It affects an individual's ability to maintain the dental structures that are necessary to obtain adequate nutrition to ensure survival and reproduction. In this study, the prevalence and pattern of odontogenic abscesses were investigated in the adult rhesus macaques from the free-ranging colony on Cayo Santiago Island in Puerto Rico. It was hypothesized that the prevalence of odontogenic abscesses is different among the sexes, different family lineages, and potentially different time intervals in the history of the colony.

Materials and Methods—The specimens were 752 adult rhesus macaques, aged 8 to 31 years, born between 1951 and 2000, from 66 matrilines. Family sizes ranged from 1 to 88 individuals. Fistulae or skeletal lesions caused by odontogenic abscesses drainage, carious lesions, tooth fractures, tooth loss, and alveolar resorption were evaluated visually.

Results—Seventy two specimens had odontogenic abscesses of varying severity, with the overall prevalence of 9.57%. Intact males had a significantly higher incidence than intact females. The

*Correspondence to: Qian Wang, Department of Biomedical Sciences, Texas A&M University College of Dentistry, 3302 Gaston Ave, Dallas, TX 75246. Tel: 214-370-7229; Fax: 214-874-4835; qian.wang@tamu.edu.

Author Manuscript Author Manuscript Author Manuscript Author Manuscript

prevalence of odontogenic abscess in individual matrilines was significantly higher than the population prevalence. Animals born between 1950 and 1965 tended to have a higher incidence of odontogenic abscesses than those contained in the collection who born in later periods (1966–1995).

Discussion—As in humans, the results of this survey suggest that a common existence of mucosa-alveolar bone pathologies in rhesus macaques may indicate familial effects interwoven with ecological and social factors. To better understand the epidemiology of these diseases in the human population, further assessments of the role played by environmental and familial effects on oral health and disease are warranted and could be evaluated in this established model using more specialized and advanced studies that include adaptation and evolution.

Keywords

Oral pathology; apical abscess; periodontal abscess; endo-periodontal combined lesion; periodontitis; matriline

INTRODUCTION

Dental diseases such as caries, enamel wear, enamel hypoplasia, odontogenic abscess, and antemortem tooth loss (AMTL) can compromise an individual's oral health and adversely affect its ability to maintain the necessary dental structures to consume enough food to ensure survival, growth, and reproduction. Thus, dental diseases serve as a measure of crucial adaptive pressure in primates, including humans (Lovell, 1990a; Lovell, 1991; Wiggs and Hall, 2003; Buzon and Bombak, 2010).

An odontogenic abscess is defined by a drainage channel in the alveolar bone due to dental disease (Buzon and Bombak, 2010). It is one of the most common dental diseases capable of causing severe maxillofacial skeletal lesions via drainage during its lifetime. Except for pericoronitis, there are three main types of odontogenic abscesses: apical abscess, periodontal abscess, and endodontic-periodontal combined lesions (Dahlén, 2002).

Apical abscesses occur when infection is outside the apical foramen and in the periapical tissues mostly due to caries, tooth wear, or fracture (Kilgore, 1989; Lovell, 1990a; Lovell, 1991; Dahlén, 2002; Wiggs and Hall, 2003). Apical abscesses with the formation of periapical granulomata or periapical cysts are chronic inflammatory responses when the dental pulp is exposed to infection due to caries, tooth wear or trauma (Dahlén G. 2002). In that scenario, the small smooth-walled cavities in the alveolus may develop into large cavities as the granulomatous tissue is replaced by fluid, forming periapical cysts. Subsequently, the cyst fluid becomes infected, with a purulent exudate in the cavities tracking through channels into the bone and surrounding soft tissue, then bursting and discharging to form apical abscesses (Möller et al., 1981; Fabricius et al., 1982 a, b; Hillson, 2001; Buzon and Bombak, 2010). Alveolar bone lesions due to pus drainage may not occur immediately, generally depending on the balance between the pathogenicity of the invasive bacteria and magnitude of the host defense (Fabricius et al., 1982a; Zappa et al., 1986; Dahlén, 2002).

Author Manuscript Author Manuscript Author Manuscript Author Manuscript

Periodontal abscesses can be caused by advanced periodontitis when a suppurative lesion is associated with periodontal breakdown, which is also called interdental abscess since they are attributed to periodontal diseases (Lovell, 1990a; Herrera et al., 2000). It usually takes several months, or even years, for chronic dental abscesses to form sinus tracts (fistulas) reflecting alveolar bone destruction from the abscess expanding through tissue that provides the least resistance (Fabricius et al., 1982a; Dahlén, 2002). Advanced periodontitis also causes soft tissue attachment loss around the tooth, alveolar bone resorption to form periodontal abscesses, and possibly the eventual antemortem loss of tooth (AMLT) (Wiggs and Hall, 2003). It has been stated that a high rate of AMTL are associated with odontogenic abscesses especially those from periodontal abscesses both in nonhuman primates and humans. (Clarke and Hirsch, 1991; Larsen, 1995; Hillson, 2001; Buzon and Bombak, 2010).

The endodontic-periodontal combined (EPC) lesions are related to concurrent pulpal and periodontal diseases that develop from the expansion of a periodontal destruction apically to join an existing periapical lesion or through the merging of an endodontic lesion with an existing periodontal lesion (Hall et al., 1967; Dahlén, 2002).

In addition to causing severe pain, maxillofacial swelling, and AMTL, odontogenic abscesses serve as a predisposing factor for cavernous sinus thrombosis, mediastinitis, airway obstruction, orbital cellulitis, deep neck space infections (DNSI) and brain abscess. These are represent complications of dental infections if they are not treated on a timely basis and thus spread to adjacent spaces or organs (Garatea-Crelgo and Gay-Escoda, 1991; Li et al., 1999; Wiggs and Hall, 2003; Zachariades et al., 2005; de Assis-Costa et al., 2013; Pourdanesh et al., 2013; Kataria et al., 2015; Ogle, 2017). These types of infections via the periodontium are also considered to be independent risk factors for systemic diseases such as cardiovascular disease (Beck and Offenbacher, 2005; Taylo et al., 2007; López-Jornet et al.,2012; Demmer and Papapanou, 2010; Ruquet et al., 2016) and diabetes (Ohlrich et al., 2010). Prior to the development of effective antibiotics, odontogenic abscesses often led to life-threatening complications, such as septic cavernous thrombosis and Ludwig's angina (Calcagno and Gibson, 1991; Busch and Shah, 1997). It was reported that over 10% of antibiotics were prescribed for odontological diseases such as acute alveolar abscesses in humans (López-Píriz, 2007). A retrospective study on the pattern of odontogenic infections in Iran showed that 5.48% of the individuals had Ludwig's angina and 22.5% of these had involvement of multi-space infections (Pourdanesh et al., 2013). In DNSI, odontogenic infections are the most common etiological factor with a prevalence of 34.21% (Kataria et al., 2015). Susceptibility and severity of dental infections and malnutrition are a clearly a synergistic relationship. Both humans and nonhuman primates with severe infectious dental disease appeared to be malnourished, and are also at a risk for further morbidity and mortality outcomes. In addition, reproductive ability is affected, with infections and malnutrition affecting females' fecundity and males' spermatogenesis (Lovell, 1991).

In nonhuman primates, the prevalence of odontogenic abscesses varies depending on the colony conditions and the sample sizes of the groups included (Jones and Cave, 1960; Hall et al., 1967; Kilgore, 1989; Lovell, 1990; Lovell, 1991; Stoner, 1995; Sauther et al., 2002). Due to a relatively small sample size or age distribution of the animals in a particular investigation, some reports of abscess prevalence within the age cohort are high (Kilgore,

Author Manuscript Author Manuscript Author Manuscript Author Manuscript

1989; Lovell, 1991). It has been stated that age is an important factor in the progression of abscesses (Kilgore, 1989; Stoner, 1995). It has been also reported that the prevalence of abscesses is higher in the African great apes and New World monkeys than in Old World monkeys. Lovell reported that Mountain Gorillas exhibited obvious alveolar destruction in the form of periodontal abscesses and different patterns of appearance in the site of ontogenetic abscesses (Lovell, 1991). For example, in great apes, apical abscesses were associated more with anterior teeth than posterior teeth, and an abscess located between two teeth was more often found in association with the posterior teeth (Lovell, 1990). For ring-tailed lemurs, apical abscesses were mostly located on the molars (Sauther et al., 2002).

The prevalence and pattern of odontogenic abscesses can be investigated using skeletons of rhesus monkeys (*Macaca mulatta*) from the free-ranging colony at the Cayo Santiago (CS) island facility, housed in the Caribbean Primate Research Center (CPRC), University of Puerto Rico. The CPRC maintains one of the most important rhesus macaque colonies on CS and one of the best and largest nonhuman primate skeletal collections for research in the world. In December, 1938, rhesus macaques were introduced onto Cayo Santiago (18.1564° N, 65.7342° W) from the Lucknow area of India (26.8470° N, 80.9470° E) which has a warm humid subtropical climate with average temperature 24.9 °C and a mean of 2,708 yearly sunshine hours; while Cayo Santiago on the other hand, is located relatively close to the equator, has a tropical monsoon climate, with average temperature 27 °C and around 3000 total yearly sunshine hours (Wang et al., 2016b). Thus the CS population has many aspects of ecology, diet, and the physical environment, differ considerably from conditions in original habitat and in the laboratory.

The CS rhesus population is considered the most homogenous large Indian-derived rhesus populations tested in the U.S.A. (Kanthaswamy et al., 2010). They are currently provided high protein commercial monkey diet (Tekland 8773 NIB Primate Diet Modified, Harland Teklad, Madison, WI) from feeders located in three large corrals at the rate of 0.23 kg per animal per day. They also forage on the abundant tropical vegetation (Marriott et al., 1989) and are geophagic (Knezevich, 1998; Mahaney et al., 1995; Marriott et al., 1989). Purified rainwater is available *ad libitum* from an automatic system located throughout the island. Following regular provision of food since 1970s, the relative abundance of food enables the CS macaques to spend less time on food foraging compared to wild populations. In CS, it was found that a group spent around 1/5 of their time eating and foraging, compared to rural wild populations with nearly 50% of their time (Marriott et al., 1989).

Rhesus macaques have a skeletal system similar to that of humans. The skeletons in the CPRC collection display osteopathologies similar to those of humans, especially the naturally-occurring degenerative conditions commonly found in elderly humans such as arthritis and osteoporosis (Pritzker and Kessler, 2012). Because of the shorter life span of rhesus macaques compared to humans, normal aging as well as age-related pathologies of the skeleton can be studied: [1] over the entire lifespan of the animal; [2] in multiple generations of ancestors through the skeletons; [3] among contemporary families; and [4] in living descendants. Studies of this type are facilitated by the large number of skeletons available for study in the collection (over 2700 greater than 0.5 years) with detailed medical records and matriline information available for many of the specimens. In addition, living

Author Manuscript Author Manuscript Author Manuscript Author Manuscript

descendants are still present in the colony, thus facilitating molecular genetic studies of familial related traits. The rhesus skeletons in this collection provide a unique research resource with which to conduct skeletal and dental studies. (DeRousseau,1978,1985; Kessler et al., 1986, 2016; Rawlins and Kessler, 1986; Châteauvert et al., 1989,1990; Grynpas et al., 1989,1993a,b; Grynpas, 1992; Pritzker et al., 1989; Rothschild et al., 1999; Cerroni, 2000; Cerroni et al., 2000, 2003; Guatelli-Steinberg and Benderlioglu, 2006; Wang et al., 2006a,b, 2007; 2016a,b; Dunbar, 2012; Kohn and Bledsoe, 2012; Pritzker and Kessler, 2012; Turnquist et al., 2012; Gonzalez et al., 2016; Kessler and Rawlins 2016; Wang et al., 2016 a,b). The CPRC skeletal collection is unique in that [1] the degree of completeness of the skeletons in the collection – the full skeleton is well preserved, [2] specimens are from free-ranging (not caged) of a closed colony originating from founders imported from India 80 years ago, [3] age-related diseases and disorders occurring naturally in this colony (spontaneously, not induced experimentally), and [4] a soft tissue collection associated with some of the skeletons (taken at necropsy). Thus the CPRC collection could be developed as a resource for the study of the importance of family lineage on oral pathology and pathologies of the skeletal system.

In previous studies, several families with specific characteristics such as increased incidence of osteoporosis and osteoarthritis, and alveolar bone loss have been identified (Cerroni et al, 2000; Turnquist et al., 2012; Gonzalez et al., 2016). The CPRC rhesus skeletal collection thus allows for the testing of a number of hypotheses relating family lineage to specific oral and skeletal pathologies. Specifically, understanding the effects of familial genetics on oral diseases will lead to a better understanding of the heritability of oral health conditions and will greatly help oral health management. Thus, a greater understanding of these conditions is a necessary precursor to managing and/or curing the oral, skeletal, and joint diseases in the human population.

In this study, the odontogenic abscesses pattern in the rhesus macaque was investigated and the relationship of age, gender, familial character, and abscess source with abscesses pattern were analyzed. At Cayo Santiago, the prevalence of linear enamel hypoplasia is higher in monkeys who were irregularly provisioned than in monkeys who experienced regular provisioning (Guatelli-Steinberg and Benderlioglu, 2006). It was thus hypothesized that the prevalence of odontogenic abscesses is different between the sexes, different family lineages, and different time intervals in the history of the colony.

MATERIALS AND METHODS

No animals were sacrificed for this study since it was based on a pre-existing skeletal collection housed in the Caribbean Primate Research Center (CPRC). The handling and care of all animals had conformed to USDA, NIH, and Puerto Rican laws, regulations, standards, policies, and guidelines in effect at the time and, since 1979, any studies involving the colony were approved by the Institutional Animal Care and Use Committee of the University of Puerto Rico Medical Sciences Campus. This research also adhered to the American Society of Primatologists Principles for the Ethical Treatment of Nonhuman Primates.

Author Manuscript Author Manuscript Author Manuscript Author Manuscript

Skull Collection

Seven hundred and fifty two (752) adult specimens derived from the skeletons of rhesus macaques (*M. mulatta*) on Cayo Santiago were inspected (Table 1). There were 283 intact males, 460 intact females, four castrated males, three intersex monkey skeletons (one pinealectomized), one hysterectomized female, and one ovariectomized female. All of them had exact information of date of birth (DOB) and date of death (DOD) except for one intact male and two intact females. All animals were born between 1951 and 2000. The ages at death were between 8.01 and 31.44 years. Among them, 739 came from 66 matrilines with family sizes in the collection ranging from 1 to 88, among these, 18 families had at least 4 skeletons collection no less than 8 years of age. The remaining 13 individuals had no family information.

Dental and Bone Examinations

Fistulae or skeletal lesions caused by odontogenic abscess drainage, carious lesions, tooth fractures, tooth loss, and alveolar resorption were visually evaluated (Lovell NC, 1990a). Apical abscesses were diagnosed when the skeletal lesions were located at apical alveolar bone corresponding apex and the periodontal alveolar bone appeared normal; periodontal abscesses were determined when the periodontal alveolar bone defects were greater than 5 mm and accompanied by obvious dental calculus attached to the crown and root (Amand and Tinkelman, 1985; Clarke et al., 1986; Wiggs and Hall, 2003; Demmer and Papapanou, 2010; Gonzalez et al., 2016). Except for abscesses existing with ATML, the causes of apical abscess were due to deep caries, serious wear, or crown fracture which exposed dental pulp to infection (Wiggs and Lobprise, 1997; Wiggs and Hall. 2003; Buzon and Bombak, 2010). Deep caries were identified by inspection and explorative examinations. A tooth involved with apical abscess had obvious deep caries lesions in which the dental explorer could be inserted into the pulp chamber and accompanied by brown or black stain (Rudney et al., 1983; Sauther et al., 2002). Serious tooth wear may result in exposure of most of dentin even the pulp chamber resulting in infection invading to the root canal as per visual examination (Wiggs and Lobprise, 1997; Sauther et al., 2002; Wiggs and Hall, 2003). Tooth fracture from trauma, wear, carious or other causes that exposed the dental pulp to infection, which were also visually identified (Wiggs and Hall, 2003; Buzon and Bombak, 2010). The degree of alveolar defect was assessed using a standard William's color-coded periodontal probe to measure the distance between the deepest level of the vertical bone defect to the cemento-enamel junction (Gonzalez et al., 2016). When skeletal lesions were related to both dental defect and periodontal infection, endo-periodontal-combined lesions were determined (Harrinon et al., 2002; Dahlén G. 2002) in which teeth had extensive periodontal alveolar resorption to root accompanied by apical alveolar bone lesion due to caries, wear or trauma. The term endo-periodontal lesions is used when it is no clear whether the infection had a periodontal or pulpal origin, or the periodontitis is caused by pulpitis (Harrinon G, 2002). Specimens with dehiscences and fenestrations that did not belong to inflammatory periodontal diseases were classified as non-pathological bony defects rather than periodontal abscess (Kakhashi et al., 1963).

Author Manuscript Author Manuscript Author Manuscript Author Manuscript

Data Analysis

Data were analyzed using the statistical analysis program Minitab 17 (Minitab Inc., State College, PA). Descriptive statistics, ANNOVA, and Chi-squared were used to assess differences among various factors. Comparisons were conducted between the sexes, families, and historical colony periods (mainly, 1951–1965,1966–1980, and 1981–1995).

RESULTS

Prevalence of odontogenic abscesses

Overall, oral diseases such as caries, antemortem tooth loss, periostities of alveolar bone, and severe temporomandibular joint osteoarthritis, in attrition to odontogenic abscesses, were present in rhesus macaques ranging from rare (caries) to common. Among the 752 specimens, 72 individuals were diagnosed as having fistulae, or alveolar lesions due to drainage from odontogenic abscesses of various degrees of severity (Table 1, Appendix Table 1). The overall prevalence was 9.57% (72/752). Among them, there were 53 intact males (18.73%), 15 intact females (3.26%), one castrated male (25.00%), two intersex (66.67%), and one hysterectomied female (100.00%) monkeys. Intact males had a significantly higher prevalence of odontogenic abscesses than intact females (Chi-Square Test: X2=50.4, P<0.0001), indicating a sex difference (Fig. 1a). The Relative Risk to be inflicted with an odontogenic abscess was 2.287 male vs. female (95% confidence interval: 1.941 to 2.696).

Types and distribution of odontogenic abscesses

In total there were 192 fistulae lesions on 199 teeth in 72 different skeletons (Tables 2–3). The fistulae primarily originated from apical disease (67.19%, 129/192), periodontal disease (22.40%, 43/192) and EPC lesions (10.42%, 20/192) (Table 2; Figs. 2–4). The prevalence of apical abscesses was significantly higher than periodontal abscesses and EPC lesions (X^2=154.7, P<0.0001). The fistulus lesions were represented in all four quadrants (Table 3). Occasionally, there were more than two fistulae occurred in one tooth, or a fused large fistula from several adjacent teeth (Fig. 5a). In terms of teeth location, anterior teeth (incisors and canines) were more involved in fistulae than premolars and molars (72.9% vs. 27.1%; X^2=83.2, P<0.0001). The Relative Risk of expressing an odontogenic abscess was 2.685 Anterior Teeth vs. Posterior Teeth (95% confidence interval: 2.106 to 3.424). Among fistulated anterior teeth, 73.8% were apical, while among fistulated posterior teeth, nearly 60% were periodontal abscess. The rates of infliction disease were comparable between maxillary and mandibular teeth, except for premolars (Maxillary vs. Mandibular: 4.5%, 12.1%).

Among all abscesses, there were four specimens with hidden mandibular fistulae under the chin (Fig. 5a–b), and five fistulae of the maxillary central incisor presented in the bottom of the nasal cavity (Fig. 2e–f). Three specimens had seven fistulae lesions in one mouth (Fig. 5c), including one specimen is a castrated male that died at the age 26.29 years (Fig. 3c). The largest abscess observed was over 10 mm in diameter (Fig. 5a).

Author Manuscript Author Manuscript Author Manuscript Author Manuscript

Caries, wear, and fracture were the principal causes of apical abscesses at Cayo Santiago, with caries being responsible for 37.21% of all apical accesses. ATML related apical accesseses were about 19.38% with some possibly due to caries as well. About 22.47 % of apical abscesses were related to wear, and about 20.93% of apical abscesses were related fracture (Table 2).

Age as a risk factor

The youngest intact female had fistulae at age 10.29 years while the lesions occurred in males by age 8.14 years, which may indicate an earlier onset of odontogenic abscesses in males than in females. The prevalence of fistulae increased with age (Tables 4, 5). In four-year-spaced intervals, the prevalence increased from 2.28% (Years 8.00–11.99) to 4.37% (Years 12.00–15.99), then to 16.03% (Years 16.00–19.99), to 30.95 % (Years 20.00–23.99), and eventually to 37.50% (Years 24.00 and above) (Table 5; Fig. 1b). Overall, the prevalence was lower below the age of 16 years than for age 16 and above (3.11% vs. 23.43% or 16/513 vs. 56/239. X^2=77.70, P<0.0001). The Relative Risk of odontogenic abscesses was 2.890 Old adult (16.00 years and above) vs. Young adult (8.00–15.99 years) (95% confidence interval: 2.426 to 3.443).

Prevalence of odontogenic abscesses in matrilines

Of 72 fistulated specimens, 71 were derived from 30 families, plus one from the group without family information while no fistulated specimens were found in the other 36 families. Of 71 specimens with family information, 56 specimens were from 16 matrilines with family members no less than 4 in the skeletal collection (Table 6), and another 15 were from 14 families with family members less than 4 in the skeletal collection.

In matrilines with high number of adult members in the skeletal collection (≥20), Families 065 (18.42%), 073 (12.32%),091 (13.73%), and 116 (10.23%) had prevalence of odontogenic abscesses higher than the overall prevalence of the population (9.57%), while Families 031 (7.84%), 058 (5.00%), 076 (9.38%), and 22 (7.41%) had a prevalence of odontogenic abscesses lower than or comparable to the overall prevalence of the population (9.57%) (Table 6). No fistulaed specimens were found in Family 092 with 34 members in the collection (M17, F17).

Prevalence of odontogenic abscesses in different periods

The incidence of fistulated specimens varied by year of birth (YOB). The incidence over 15-year-long periods was 19.2% for animals born between 1951 and 1965, 8.5% between 1966 and 1980, and 6.9% between 1981 and 1990 (Table 7; Fig. 3). The early period (1951–1965) had significantly higher incidence of fistulae than later periods (1966–1980, 1981–1995) (19.2% vs. 7.7% or 28/116 vs. 44/518. X^2=22.21, P<0.0001). The Relative Risk to be inflicted with odontogenic abscesses was 2.445 Born 1951–1965 vs. Born 1966–1995 (95% confidence interval: 1.726 to 3.465).

Author Manuscript Author Manuscript Author Manuscript Author Manuscript

DISCUSSION

Odontogenic abscesses are one of the most common dental diseases that can cause various maxillofacial skeletal lesions. The maintenance of these dental structures in good health and condition is necessary for humans and animals to acquire and consume adequate nutrition to ensure normal growth and development, survival and reproduction. In this study, the prevalence and pattern of odontogenic abscesses were systematically investigated in the skeletons of adult rhesus macaques from Cayo Santiago Puerto Rico. There were significant differences in the prevalence of odontogenic abscesses between sexes, between different age groups, between families, and between early and late time intervals in the history of the colony (Table 8). The hypotheses that the prevalence of odontogenic abscesses is different between the sexes, different family lineages, and different periods, is not rejected.

Unlike many previous studies which were based on smaller samples or samples across different colonies, this survey was based on a large number of specimens obtained from a skeletal collection of a single population over a 50-year-long period, with detailed knowledge of age, sex, birth/death date, and matriline background for nearly all the animals.

The overall prevalence of odontogenic abscesses in rhesus macaques from Cayo Santiago was 9.57% for animals aged 8.00 years and above, which is lower than that of Gorillas (12.9%. Lovell, 1990), and of ring-tailed lemurs (19.05%. Sauther et al., 2002). It is also reported that abscesses are less prevalent in Old World monkeys than in African apes and New World monkeys, while the interdental abscesses caused by periodontal alveolar destruction were reported to be obvious in mountain gorillas (Lovell, 1991). Occasionally the frequency of caries and apical abscess is inconsistent although a positive correlation between the two types of lesions is expected. If the tooth is lost before death due to caries, the abscess is usually identifiable although it cannot be scored. For example, the caries frequency of howler monkeys was low but the abscess frequency was high (Lovell, 1990). Ecological separation of the sexes or different colonies with one species might be responsible for different manifestation of oral pathologies, in addition to dental growth and development (Stoner, 1995; Guatelli-Steinberg et al., 2008; Guatelli-Steinberg et al., 2009). Likewise, differences in dietary patterns and ecological factors, plus levels of survival stress could have combined effects on health status and pathology.

The prevalence of dental abscesses varies in human populations and nonhuman primates (Table 9). However, except for some abscess prevalence studies based on apical periodontitis (AP) or chronic periodontitis (CP) (Kaldahl et al., 1996; Nair et al.,1996; McLeod et al., 1997; Vier and Figueiredo, 2002; Omoregie et al., 2011), generally data on the prevalence of odontogenic abscesses in humans are limited and direct comparisons among them are often hard to make due to differences in sample size, demographic structure, dietary behavior, oral hygiene recognition levels, and the design of the investigation (patients or skeleton-based; visual screening or imaging-technique aided). Basically, acute dento-alveolar abscesses, pericoronitis, and periodontal abscesses are the leading causes of the need for emergency care of infections (Herrera et al., 2000). It appears that the odontogenic abscess prevalence in humans is lower than that of nonhuman primates (Table 9), which might be due to better personal oral health care, better diet and nutrition, and access to professional dental care.

Author Manuscript Author Manuscript Author Manuscript Author Manuscript

In living subjects, it has been demonstrated that the combination of radiographic and clinical examinations could improve the periapical lesions detection (Chazel et al. 2005; Lucas et al., 2010), yet the odontogenic abscesses represented by maxillofacial drainage channels in dry skulls could be evaluated visually (Buzon and Bombak, 2010). Some alveolar bone lesions were limited around the apex and did not penetrate the periosteum, so they could not be observed. This might have influenced the prevalence derived from visual screenings. In the future, radiographic or CT images could be used to investigate the odontogenic abscesses to obtain more accurate results.

Age has been shown to be an essential factor in the progression of dental disease, such as abscesses and horizontal bone loss (Kilgore, 1989; Stoner, 1995). It has been demonstrated that there are significant differences between young and old adults in terms of the numbers of individuals afflicted with dental pathologies (Stoner, 1995). In this study, the specimens consisted of adult specimens of 8 years old and above. The prevalence in animals 16 years and older and above was significantly higher than that of the younger groups, which was consistent with Kilgore's findings. As the monkeys aged, their tooth wear changed gradually from lightly worn to severely worn (Wang et al., 2016b). A high level of tooth wear could cause caries resulting in fracturing and dental pulp exposure (Hillson, 2001), and further cause abscesses (Lovell NC. 1990a). It was also observed that wear increased or accumulated with age and occlusal excessive load wear had position correlations with periapical lesions in ancient human (Molnar, 2008). Some believe that tooth wear might also serve as a form of tooth cleaning, encouraging healthy gum and root relationships by eliminating the deposition of cementum (Hall and German, 1975; Chazel et al., 2005). From these results, it can be concluded that age is an influence factor for the prevalence of odontogenic abscesses in adult rhesus monkeys from Cayo Santiago.

There is no consensus on the influence of sex on the oral health. Previous skeleton-based studies on Bornean orangutans and ring-tailed lemurs indicate that females exhibit a higher percentage of dental pathologies including dental abscess than that of males. This might be associated with greater fruit eating in dominant females, especially older ones (Stoner, 1995; Sauther et al, 2001; Sauther et al, 2002). Examination of living animals reveals that in CS rhesus macaques, males have higher tooth fracture and loss than females, with nearly half of males age 10 years and above have teeth missing or broken, or both (Wang et al., 2016b), corresponding to the higher rate of odontogenic abscesses found in male skeletons. In the present study, we found the abscess incidence in intact females (3.26%) was significantly lower than that of intact males (18.73%). Several studies addressing the relationship between sex steroids and oral health and different consequences in males and females also indicate a higher prevalence of periodontal diseases in men than in women (DeWitte, 2012; Haytac et al, 2013; Bonsall, 2014; Wang et al., 2016a), while some studies have suggested premenopausal women's oral health could be more compromised than that of men due to the menstrual cycle and pregnancy (i.e., Streckfus et al., 1998; Lukacs, 2011). One specimen from Cayo Santiago was a castrated male who died at the age 26.29 years. This monkey had seven fistulae lesions possibly due to the long-term low level of sex steroids (Wang et al., 2016a).

Author Manuscript Author Manuscript Author Manuscript Author Manuscript

For CS rhesus macaques, females normally have earlier dental eruption than males except the third molars (Wang, 2012) and females have earlier dental maturity (around age 4 years) corresponding to their earlier sexual maturity (3 years) than males (around 5 to 6). In terms of material maturity, females have later dental maturity (age 6.5 years) than males (6 years). Thus sex specificity in the timing of dental eruption might suggest that the dental maturity is under different hormonal controls corresponding to sex-based differences (Wang, 2012). The much higher prevalence of odontogenic abscesses in males than female rhesus macaques from CS further indicates the role of sex steroids in oral pathology (Wang et al., 2016a,b) in addition to dentition (Guatelli-Steinberg et al., 2008, 2009; Wang, 2012). The pathogenesis is yet to be fully explored and clarified.

The incidence of fistulae types varied with tooth location. A study on wild ring-tailed lemurs found most of apical abscesses located on the molars (Sauther et al., 2002), which is at variance with this study. In the CS rhesus macaques, odontogenic abscesses were seen in all quadrants, with more anterior teeth inflicted with fistulae than posterior teeth. Periapical abscesses prevailed among fistulated anterior teeth and periodontal abscesses prevailed among fistulated posterior teeth. Cutaneous sinus tracts originated from teeth are often initially misdiagnosed and inappropriately treated due to their rare occurrence and not obvious symptoms or signs in nearly half the individuals affected (Javid & Barkhordar., 1989; Cantatore et al., 2002). In our investigation, we found there were four specimens with hidden mandibular fistulae under the chin, which was similar to cutaneous sinus tracts of human performance clinically (Johnson et al., 1999; Cantatore et al., 2002 Pasternak-Júnior et al., 2009). In addition, there were five fistulae of maxillary central incisor in the bottom of nasal cavity, which was too hidden to be found easily. If these fistulae were not in advance or left untreated, infection related to the teeth might have spread to adjacent tissues, such as sinus, orbits, deep fascial spaces of the neck, and even intracranial and thoracic structures, resulting in a significant increase in the animals' morbidity and mortality (Zachariades et al., 2005; Taylo et al., 2007; de Assis-Costa et al., 2013; Pourdanesh et al., 2013; Shweta, 2013; Brown et al., 2016; Ogle, 2017).

Selected matrilineal families had a higher prevalence of odontological abscesses than the overall prevalence of the population with most of the fistulae associated with periapical infections. It is unclear whether apical abscesses are more specifically related to hereditary factors and warrants further study. Several studies have demonstrated a clear familial relationship of the onset and severity of periodontitis in both humans (Armitage and Cullinan, 2010; Carlsson et al., 2006; Hodge et al., 2000; Kinane et al., 2005), and nonhuman primates including rhesus macaques (Gonzalez et al., 2016) and baboons (Miller et al., 1995).

While studying the receding alveolar bone as a sign of periodontitis using the same CS skeletal collection for animals age 5 years and older, Gonzalez et al. (2016) detected clear family differences, i.e., a significant increase in the frequency of alveolar bone resorption in animals between 10 and 17 years old from the 065 matriline compared to Family 116 and Family 22. In addition, animals older than17 years of age from Family 065 and Family 116 had more extensive periodontitis expression than those from Family 22. In the present study with samples no younger than 8 years old, both Family 065 and Family 116 have higher

Author Manuscript Author Manuscript Author Manuscript Author Manuscript

odontogenic abscesses incidences (18.42% and 10.23%) than Family 22 (4.55%). In this regard, Family 22 had better oral health status than Family 065 and Family 116. Periodontal abscesses come from periodontitis but not all periodontitis causes periodontal abscesses, yet animals tending to have a higher risk of periodontitis may have a higher risk for odontogenic abscesses as well.

The CPRC nonhuman primate colony and skeletal collection has the potential to yield substantial data on the importance of family lineage to bone health, representing a significant, but largely untapped, resource for studies of the normal growth and pathologies of the skeletal system of both nonhuman and humans primates. Further assessments of the role played by familial effects on oral health and disease are warranted to establish models for more specialized and advanced investigations such as quantitative trait locus studies, to identify chromosomal regions that influence oral health in families, and the general population. A better understanding of these conditions is a necessary precursor to managing and/or curing these diseases in the humans.

It is intriguing that animals born in the early period (1951–1965) had a significantly higher percentage of abscesses than later periods (1966–1980 and 1981–1995). One explanation was that animals of the late periods had lower average age at death, thus the lower incidence during later periods could be related to overall younger samples. However, it might be related to harsh living conditions experienced by animals of the early period. The animals were among the early generations born in the Caribbean area from settlers whose natural habitat was India and there was a period of famine before routine food provisions were established. Guatelli-Steinberg and Benderlioglu (2006) found that the prevalence of linear enamel hypoplasia is higher in monkeys who were irregularly provisioned (comparable to early period in this study) than in monkeys who experienced regular provisioning (corresponding to late period in this study), a similar pattern found in odontogenic abscess, indicating that the odontogenic abscess is a sensitive indicator of systemic physiological stress, such as nutrition status. A systematic study on the life history, survival, adaptation, health, aging, pathology, ecology, and evolution within the context of its interaction with the environment at Cayo Santiago, and a comparative study between the CS colony and decedents of the population still living in the Lucknow region of India, would be very informative for better understanding of primate health, human adaption and evolution.

CONCLUSION

In this study, the prevalence and pattern of odontogenic abscesses were investigated in the skeletons of adult rhesus macaques from the free-ranging colony on Cayo Santiago, Puerto Rico. Seventy two specimens were found to have odontogenic abscesses of varying severity, with overall prevalence of odontogenic abscesses at 9.57%. Males had a significantly higher incidence than females. The prevalence of odontogenic abscesses in some matrilines was significantly higher than the general population and animals born between 1950 and 1965 tended to have a higher incidence of odontogenic abscesses than those born in later periods (1966–1995). These results suggest that mucosa-alveolar bone pathologies in rhesus macaques, as in humans, are fairly common, and that genetics, social factors and the environment play a role. Further assessments of the role played by environmental and

Author Manuscript Author Manuscript Author Manuscript Author Manuscript

familial effects on oral health and disease are warranted to establish models for more specialized and advanced studies to better understand the epidemiology of these diseases in the human population, including adaptation and evolution.

ACKNOWLEDGEMENTS

The CPRC Skeletal Collection has been supported by NIH contracts NIH-71–2003 and RR-7–2115; grants P40-RR01293, P40-RR03640 and P40-OD012217; and NSF grant SBR-84–06541. Current CPRC Director Dr. Melween I. Martinez Rodriguez is thanked for her support of this study. Additional support came from the University of Puerto Rico Medical Sciences Campus. Special thanks are extended to the following CPRC staff members: Edgar Davila, Myrna Reyes and Alberto Clemente for performing skeletal preparations; and Dr. Jean Turnquist, Mrs. Myriam Viñales, the late Dr. Nancy Hong, Dr. John Cant, and Dr. Donald Dunbar for their curatorial work with the skeletal collection. Dr. Richard Rawlins, Dr. Janis Gonzalez-Martinez, Dr. Robert W. Kensler, Dr. Amy Lee, Dr. Jerry Feng, Dr. Hu Zhao, and Dr. Celeste Abraham are thanked for their support and help. Co-author Terry B. Kensler, who currently manages the collection, is thanked for her excellent curatorial skills. Dr. Li Sun is especially thanked for her help, support and patience.

Appendix

Author Manuscript Author Manuscript Author Manuscript Author Manuscript

Appendix Table 1

Seventy two specimens with odontogenic abscesses from Cayo Santiago (age 8 years and above)

	Museum Catalogue Number	Sex	Age	Matriline	Number of lesions	Number of teeth involved	Apical lesions	Periodontal lesions	Endo-periodontal lesions	Upper Anterior teeth	Low Anterior teeth	Upper Premolar	Lower Premolar	Upper Molar	Lower Molar
1	24	F	10.3	64	1	1	1	0	0	0	1	0	0	0	0
2	135	F	18.4	131	2	2	1	1	0	0	1	0	1	0	0
3	256	M	18.8	UNK	7	7	7	0	0	4	2	0	1	0	0
4	257	M	11.5	102	3	3	0	2	1	0	2	1	0	0	0
5	304	M	13.4	81	5	6	4	0	1	0	4	0	2	0	0
6	347	F-Hysterectomized	22.0	84	1	1	0	1	0	0	0	1	0	0	0
7	348	M	14.8	109	4	4	4	0	0	0	2	0	2	0	0
8	365	M	9.0	105	1	1	0	1	0	1	0	0	0	0	0
9	373	F	20.7	65	1	1	1	0	0	0	1	0	0	0	0
10	435	F	23.7	62	1	1	1	0	0	0	0	0	1	0	0
11	441	F	17.7	22	1	1	1	0	0	0	1	0	0	0	0
12	448	M	18.6	119	2	2	1	0	1	0	0	1	1	0	0
13	498	M	21.2	BU	2	2	1	1	0	2	0	0	0	0	0
14	524	M	14.6	DM	1	1	0	1	0	0	1	0	0	0	0
15	529	M	13.5	90	3	3	2	0	1	2	1	0	0	0	0
16	603	M	12.8	73	1	1	1	0	0	1	0	0	0	0	0
17	643	M	22.1	81	3	3	2	0	1	2	1	0	0	0	0
18	647	M-Castrated	27.0	76	7	8	1	5	1	1	1	0	0	3	3
19	663	Intersex (Pinealectomized)	22.1	115	5	4	3	1	1	1	2	0	1	0	0
20	782	M	22.6	128	1	4	1	0	0	0	4	0	0	0	0
21	793	F	21.4	73	2	2	2	0	0	1	1	0	0	0	0
22	799	M	16.5	31	1	1	1	0	0	1	0	0	0	0	0
23	814	M	10.2	22	1	1	1	0	0	0	1	0	0	0	0
24	820	M	9.8	AC	1	1	1	0	0	0	0	0	1	0	0
25	826	F	24.8	80	3	3	3	0	0	1	1	1	0	0	0

Author Manuscript Author Manuscript Author Manuscript Author Manuscript

	Museum Catalogue Number	Sex	Age	Matriline	Number of lesions	Number of teeth involved	Apical lesions	Periodontal lesions	Endo-periodontal lesions	Upper Anterior teeth	Low Anterior teeth	Upper Premolar	Lower Premolar	Upper Molar	Lower Molar
26	834	Intersex	19.8	70	5	5	2	3	0	0	1	1	2	0	1
27	846	M	26.5	58	3	3	1	0	2	0	2	0	1	0	0
28	1010	M	20.6	97	4	4	1	2	1	0	2	0	1	1	0
29	1161	M	24.7	DM	1	1	0	0	1	1	0	0	0	0	0
30	1210	M	25.2	73	4	5	2	1	1	0	3	0	1	1	0
31	1526	M	12.1	76	1	1	1	0	0	1	0	0	0	0	0
32	1570	M	19.7	91	3	3	3	0	0	2	0	1	0	0	0
33	1600	M	22.9	114	3	3	3	0	0	2	1	0	0	0	0
34	2023	M	15.3	73	1	1	1	0	0	1	0	0	0	0	0
35	2120	M	28.3	65	3	3	1	1	1	1	2	0	0	0	0
36	2961	M	18.4	65	3	3	3	0	0	1	1	0	1	0	0
37	2964	M	18.7	91	2	3	0	1	1	0	1	0	0	0	2
38	2965	M	18.7	22	3	3	2	0	1	2	1	0	0	0	0
39	2971	M	29.1	65	4	4	2	2	0	2	1	0	0	1	0
40	3048	M	8.1	65	1	1	1	0	0	1	0	0	0	0	0
41	3066	M	17.3	73	5	5	5	0	0	3	2	0	0	0	0
42	3136	M	18.2	31	2	2	1	1	0	0	1	0	1	0	0
43	3251	M	21.9	73	6	6	5	1	0	1	3	0	0	2	0
44	3284	M	20.6	22	2	2	2	0	0	2	0	0	0	0	0
45	3289	F	22.0	116	1	1	1	0	0	0	1	0	0	0	0
46	3306	F	13.2	31	2	2	2	0	0	1	1	0	0	0	0
47	3556	M	99.0	91	2	1	2	0	0	1	0	0	0	0	0
48	3602	M	23.9	76	5	5	3	0	2	4	1	0	0	0	0
49	3912	F	20.0	73	2	2	1	1	0	0	1	0	0	1	0
50	3915	M	19.8	76	3	3	3	0	0	1	2	0	0	0	0
51	3922	M	25.5	31	3	3	3	0	0	0	2	0	1	0	0
52	3927	M	20.2	91	3	3	2	1	0	1	2	0	0	0	0
53	3928	M	18.4	76	2	2	2	0	0	2	0	0	0	0	0

Author Manuscript Author Manuscript Author Manuscript Author Manuscript

	Museum Catalogue Number	Sex	Age	Matriline	Number of lesions	Number of teeth involved	Apical lesions	Periodontal lesions	Endo-periodontal lesions	Upper Anterior teeth	Low Anterior teeth	Upper Premolar	Lower Premolar	Upper Molar	Lower Molar
54	3944	M	26.1	EA	4	4	2	2	0	2	0	0	0	2	0
55	3984	M	19.4	116	4	4	2	1	1	3	0	0	0	1	0
56	4067	M	17.9	91	1	1	0	1	0	1	0	0	0	0	0
57	4128	F	99.0	65	1	1	1	0	0	0	0	1	0	0	0
58	4168	M	10.1	116	2	2	1	1	0	1	1	0	0	0	0
59	4316	F	23.4	DM	4	4	0	4	0	1	2	0	1	0	0
60	4327	M	22.4	116	2	2	2	0	0	1	1	0	0	0	0
61	4436	M	20.8	RB	2	2	2	0	0	2	0	0	0	0	0
62	4471	M	22.9	116	7	7	5	1	1	3	2	0	2	0	0
63	4498	M	16.2	73	3	3	3	0	0	2	0	1	0	0	0
64	4505	M	17.3	76	4	4	3	1	0	4	0	0	0	0	0
65	4551	M	21.0	4	1	1	1	0	0	0	1	0	0	0	0
66	4554	F	22.0	116	2	2	0	2	0	0	1	0	1	0	0
67	4575	M	22.1	116	1	1	0	1	0	1	0	0	0	0	0
68	4579	M	23.7	116	2	3	2	0	0	1	1	0	1	0	0
69	4592	F	19.9	DM	1	1	1	0	0	1	0	0	0	0	0
70	4627	M	20.7	116	6	7	3	2	1	3	2	0	2	0	0
71	4651	M	18.1	73	5	5	5	0	0	2	0	1	0	0	2
72	4669	F	19.8	65	1	1	1	0	0	1	0	0	0	0	0
	TOTLE				192	199	129	43	20	76	69	9	25	12	8

Author Manuscript Author Manuscript Author Manuscript Author Manuscript

REFERENCE

Amand WB, Tinkelman CL. 1985 Oral disease in captive wild animals In: Harvey CE, editor. Veterinary dentistry. Philadelphia: WB Saunders Co p 289–311.

Ahl DR, Hilgeman JL, Snyder JD. 1896 Periodontal emergencies. Dent Clin North Am 30: 459–472.

Armitage GC, Cullinan MP. 2010 Comparison of the clinical features of chronic and aggressive periodontitis. Periodontology 2000 53:12–27. [PubMed: 20403102]

Azodo CC, Chukwumah NM, Ezeja EB. 2012 Dentoalveolar abscess among children attending a dental clinic in Nigeria. Odontostomatol Trop 35: 41–46. [PubMed: 23316599]

Beck JD, Offenbacher S. 2005 Systemic Effects of Periodontitis: Epidemiology of Periodontal Disease and Cardiovascular Disease. J Periodontol 76: 2089–2100.

Bhaskar SN. 1996 Oral surgery--oral pathology conference No. 17, Walter Reed Army Medical Center. Periapical lesions--types, incidence, and clinical features. Oral Surg Oral Med Oral Pathol 21: 657–671.

Bonsall L. 2014 A comparison of female and male oral health in skeletal populations from late Roman Britain: implications for diet. Arch Oral Biol 59: 1279–1300. [PubMed: 25150533]

Brothwell D, Ghiabi E. 2009 Periodontal health status of the Sandy Bay First Nation in Manitoba, Canada. Int J Circumpolar Health 68: 23–33. [PubMed: 19331239]

Brown T, Beaufrère H, Brisson B, Laniesse D, Zur Linden A. 2016 Ventral rhinotomy in a pet rabbit (Oryctolagus cuniculus) with an odontogenic abscess and sub-obstructive rhinitis. Can Vet J 57: 873–878. [PubMed: 27493289]

Busch RF, Shah D. 1997 Ludwig's angina: improved treatment. Otolaryngol Head Neck Surg 117: 172–175.

Buzon MR, Bombak A. 2010 Dental disease in the Nile Valley during the New Kingdom. Int J Osteoarchaeol 20:371–387.

Cantatore JL, Klein PA, Lieblich LM. 2002 Cutaneous dental sinus tract, a common misdiagnosis: a case report and review of the literature. Cutis 70: 264–267. [PubMed: 12469779]

Carlsson G, Wahlin YB, Johansson A, Olsson A, Eriksson T, Claesson R, Hänström L, Henter JI. 2006 Periodontal disease in patients from the original Kostmann family with severe congenital neutropenia. J Periodontol 77: 744–751. [PubMed: 16584360]

Cerroni AM. 2000 The pathology and epidemiology of spontaneous diseases and disorders of the spine in the Rhesus Macaques of Cayo Santiago. Ph.D. Thesis, University of Toronto, Toronto.

Cerroni AM, Tomlinson GA, Turnquist JE, Grynpas MD. 2000 Bone mineral density, osteopenia, and osteoporosis in the rhesus macaques of Cayo Santiago. Am J Phys Anthropol 113:389–410. [PubMed: 11042540]

Cerroni AM, Tomlinson GA, Turnquist JE, Grynpas MD. 2003 Effect of parity on bone mineral density in female rhesus macaques from Cayo Santiago. Am J Phys Anthropol 121: 252–269. [PubMed: 12772213]

Châteauvert JM, Pritzker KP, Kessler MJ, Grynpas MD. 1989 Spontaneous osteoarthritis in rhesus macaques. I. Chemical and biochemical studies. J Rheumatol 16: 1098–1104. [PubMed: 2585407]

Châteauvert JM, Grynpas MD, Kessler MJ, Pritzker KP. 1990 Spontaneous osteoarthritis in rhesus macaques. II. Characterization of disease and morphometric studies. J Rheumatol 17: 73–83. [PubMed: 2313678]

Chazel JC, Valcarel J, Tramini P, Pellisier B. 2005 Coronal and apical lesions, environmental factors: study in a modern and an archaeological population. Clin Oral Investig 9: 197–202.

Clarke NG, Hirsch RS. 1991 Tooth dislocation: the relationship with tooth wear and dental abscesses. Am J Phys Anthropol 85: 293–298. [PubMed: 1897601]

Clarke NG, Carey SE, Srikandi W, Hirsch RS, Leppard PI. 1986 Periodontal disease in ancient populations. Am J Phys Anthropol 71: 173–183. [PubMed: 3541645]

Dahlén G. 2002 Microbiology and treatment of dental abscesses and periodontal-endodontic lesions. Periodontol 2000 28: 206–239.

de Assis-Costa MD, Santos GS, Maciel J, Sonoda CK, de Melo WM. 2013 Odontogenic infection causing orbital cellulitis in a pediatric patient. J Craniofac Surg 24: 526–529. [PubMed: 23524733]

Author Manuscript Author Manuscript Author Manuscript Author Manuscript

Demmer RT, Papapanou PN. 2010 Epidemiologic patterns of chronic and aggressive periodontitis. Periodontol 2000 53: 28–44. [PubMed: 20403103]

DeRousseau CJ. 1978 Osteoarthritis in Non-Human Primates: A locomotor model of joint degeneration. PH.D. Dissertation. Northwestern University, Evanston, Illinois.

DeRousseau CJ. 1985 Aging in the musculoskeletal system of rhesus monkeys III. Bone loss. Am J Phys Anthropol 68: 157–167. [PubMed: 4061606]

DeWitte SN. 2012 Sex differences in periodontal disease in catastrophic and attritional assemblages from medieval London. Am J Phys Anthropol 149: 405–416. [PubMed: 22976824]

Dunbar DC. 2012 Physical anthropology at the Caribbean Primate Research Center: Past, present, and future In: Wang Q, editor. Bones, Genetics, and Behavior of Rhesus Macaques: Macaca mulatta of Cayo Santiago and Beyond. New York: Springer p 1–35.

Fabricius L, Dahlén G, Öhman A, Möller Å. 1982a Predominant indigenous oral bacteria isolated from infected root canals after varied times of closure. Scand J Dent Res 90: 134–144. [PubMed: 6951255]

Fabricius L, Dahlén G, Holm S, Möller Å. 1982b Influence of combinations of oral bacteria on periapical tissues of monkeys. Scand J Dent Res 90: 200–206. [PubMed: 7051261]

Garatea-Crelgo J, Gay-Escoda C. 1991 Mediastinitis from odontogenic infection. Report of three cases and review of the literature. Int J Oral Maxillofac Surg 20: 65–68. [PubMed: 2051049]

Gonzalez GA, Orraca L, Kensler TB, Gonzalez-Martinez J, Maldonado E, Ebersole JL. 2016 Familial periodontal disease in the cayo santiago rhesus macaques. Am J Primatol 78:143–151. [PubMed: 25708960]

Gray JL, Flanary DB, Newell DH. 1994 The prevalence of periodontal abscess. J Indiana Dent Assoc 73:18–20, 22–23.

Grynpas MD, Huckell B, Pritzker KPH, Hancock RGV, Kessler MJ. 1989 Bone mineral and osteoporosis in aging rhesus monkeys. P R Health Sci J 8: 197–204. [PubMed: 2780964]

Grynpas MD. 1992 Spinal osteoporosis in the rhesus macaque (abstract). Symposium: Osteoarthritis and bone pathology in nonhuman and human primates. Am J Primatol 27: 38.

Grynpas MD, Huckell CB, Reichs KJ, DeRousseau CJ, Greenwood C, Kessler MJ. 1993a Effect of age and osteoarthritis on bone mineral in rhesus monkey vertebrae. J Bone Miner Res 8: 909–917. [PubMed: 8213253]

Grynpas MD, Hancock RGV, Greenwood C, Turnquist J, Kessler MJ. 1993b The effects of diet, age and sex on the mineral content of primate bones. Calcif Tissue Int 52: 399–405. [PubMed: 8504378]

Guatelli-Steinberg D, Benderlioglu Z. 2006 Brief communication: Linear enamel hypoplasia and the shift from irregular to regular provisioning in Cayo Santiago rhesus monkeys (Macaca mulatta). Am J Phys Anthropol 131: 416–419. [PubMed: 16617431]

Guatelli-Steinberg D, Ferrell RJ, Spence J, Hubbard A, Talabere T, Schmidt S. 2009 Sex differences in anthropoid mandibular canine lateral enamel formation. Am J Phys Anthropol 140: 216–233. [PubMed: 19350641]

Guatelli-Steinberg D, Sciulli P, Betsinger T. 2008 Dental crown size and sex hormone concentrations: another look at the development of sexual dimorphism. Am J Phys Anthropol 137: 324–333. [PubMed: 18615561]

Hall R, German T. 1975 Dental pathology, attrition, and occlusal surface form in a prehistoric sample from British Columbia. Syesis 8: 275–289. [PubMed: 11633346]

Hall WB, Grupe HE, Claycomb CK. 1967 The periodontium and periodontal pathology in the howler monkey. Arch Oral Biol 12: 359–365. [PubMed: 4960732]

Harrinon G, Steiner D, Ammons W. 2002 The periodontal-endodontic controversy. Periodontol 2000 30: 123–130. [PubMed: 12236902]

Haytac MC, Ozcelik O, Mariotti A. 2013 Periodontal disease in men. Periodontol 2000 61: 252–265. [PubMed: 23240953]

Herrera D, Roldán S, Sanz M. 2000 The periodontal abscess: a review. J Clin Periodontol 27: 377–386. [PubMed: 10883866]

Author Manuscript Author Manuscript Author Manuscript Author Manuscript

Hillson SW. 2001 Recording dental caries in archaeological human remains. Int J Osteoarchaeol 11: 249–289.

Hodge PJ, Teague PW, Wright AF, Kinane DF. 2000 Clinical and genetic analysis of a large North European Caucasian family affected by early-onset periodontitis. J Dent Res 79: 857–863. [PubMed: 10765960]

Holtfreter B, Schwahn C, Biffar R, Kocher T. 2009 Epidemiology of periodontal diseases in the Study of Health in Pomerania. J Clin Periodontol 36:114–123. [PubMed: 19207886]

Javid B, Barkhordar RA. 1989 Chronic extraoral fistulae of dental origin. Compend Contin Edu Dent 10: 8–14.

Johnson BR, Remeikis NA, Van Cura JE. 1999 Diagnosis and treatment of cutaneous facial sinus tracts of dental origin. J Am Dent Assoc 130: 832–836. [PubMed: 10377641]

Kakhashi S, Baer P, White CL. 1963 Comparative pathology of periodontal disease. I. Gorilla. Oral Surg Oral Med Oral Pathol 16: 397–406. [PubMed: 13965037]

Kaldahl WB, Kalwarf KL, Patil KD, Molvar MP, Dyer JK. 1996 Longterm evaluation of periodontal therapy (I). Response to 4 therapeutic modalities. J Periodontol 67: 93–102. [PubMed: 8667142]

Karki AJ, Monaghan N, Morgan M. 2015 Oral health status of older people living in care homes in Wales. Br Dent J. 219: 331–334. [PubMed: 26450249]

Kataria G, Saxena A, Bhagat S, Singh B, Goyal I, Vijayvergia S, Sachdeva P. 2015 Prevalence of odontogenic deep neck space infections (DNSI): a retrospective analysis of 76 cases of DNSI Int J Otorhinolaryngol Head Neck Surg 1: 11–16.

Kessler MJ, Rawlins RG. 2016 A 75-Year Pictorial History of the Cayo Santiago Rhesus Monkey Colony. Am J Primatol 78: 6–43. [PubMed: 25764995]

Kessler MJ, Turnquist JE, Pritzker KPH, London WT. 1986 Reduction of passive extension and radiographic evidence of degenerative knee joint diseases in cage-raised and free-ranging aged rhesus monkeys (Macaca mulatta). J Med Primatol 15: 1–9. [PubMed: 3701835]

Kessler MJ, Wang Q, Cerroni AM, Grynpas MD, Velez ODG, Rawlins RG, Ethun KF, Wimsatt JH, Kensler TB, Pritzker KPH. 2016 Long-term effects of castration on the skeleton of male rhesus monkeys (Macaca mulatta). American Journal of Primatology 78:152–166. [PubMed: 25771746]

Kinane DF, Shiba H, Hart TC. 2005 The genetic basis of periodontitis. Periodontol 2000 39: 91–117. [PubMed: 16135066]

Kilgore L. 1989 Dental pathologies in ten free-ranging chimpanzees from Gombe National Park, Tanzania. Am J Phys Anthropol 80: 219–227. [PubMed: 2801914]

Kohn LAP, Bledsoe Z. 2012 Genetic and Social Group Influences on Postcranial Morphology in Rhesus Macaques of Cayo Santiago In: Wang Q. editor. Bones, genetics, and behavior of Rhesus macaques: Macaca mulatta of Cayo Santiago and beyond. New York: Springer p 117–129.

Larsen CS. 1995 Biological changes in human populations with agriculture. Annu Rev Anthropol 24: 185–213.

Lewis MA, Meechan C, MacFarlane TW, Lamey PJ, Kay E. 1989 Presentation and antimicrobial treatment of acute orofacial infections in general dental practice. Br Dent J 166: 41–45. [PubMed: 2917089]

Li X, Tronstad L, Olsen I. 1999 Brain abscesses caused by oral infection. Endod Dent Traumatol 15: 95–101. [PubMed: 10530150]

Lommer MJ, Verstraete FJ. 2000 Prevalence of odontoclastic resorption lesions and periapical radiographic lucencies in cats: 265 cases (1995–1998). J Am Vet Med Assoc 217: 1866–1869. [PubMed: 11132894]

Lovell NC. 1990a Skeletal and dental pathology of free ranging mountain gorillas. Am J Phys Anthropol 81: 399–412. [PubMed: 2327480]

Lovell NC. 1991 An evolutionary framework for assessing illness and injury in nonhuman primates. Yearb Phys Anthropol 34: 117–155.

López-Jornet P, Berná-Mestre JD, Berná-Serna JD, Camacho-Alonso F, Fernandez-Millan S, Reus-Pintado M. 2012 Measurement of Atherosclerosis Markers in Patients With Periodontitis: A Case-Control Study. J Periodontol 83: 690–698. [PubMed: 22060049]

Author Manuscript Author Manuscript Author Manuscript Author Manuscript

López-Píriz R, Aguilar L, Giménez MJ. 2007 Management of odontogenic infection of pulpal and periodontal origin. Med Oral Patol Oral Cir Bucal 12: 154–159.

Lucas S, Sevin A, Passarius O, Esclassan R, Crubezy E, Grimoud AM. 2010 Study of dental caries and periapical lesions in a mediaeval population of the southwest France: differences in visual and radiographic inspections. Homo 61: 359–372. [PubMed: 20813364]

Lukacs JR. 2011 Sex differences in dental caries experience: clinical evidence, complex etiology, and similar studies. Clin Oral Investig 15: 649–656.

Marques MD, Moreira B, Eriksen HM. 1998 Prevalence of apical periodontitis and results of endodontic treatment in an adult, Portuguese population. Int Endod J. 31: 161–165. [PubMed: 10321161]

McLeod DE, Lainson PA, Spivey JD. 1997 Tooth loss due to periodontal abscess: a retrospective study. J Periodontol 68: 963–966. [PubMed: 9358362]

McWhorter AG, Seale NS. 1991 Prevalence of dental abscess in a population of children with vitamin D-resistant rickets. Pediatr Dent 13: 91–96. [PubMed: 1652746]

Miller DR, Aufdemorte TB, Fox WC, Waldrop TC, Mealey BL, 1995 Brunsvold MA. Periodontitis in the baboon: a potential model for human disease. J Periodontal Res. 30: 404–409. [PubMed: 8544104]

Möller Å, Fabricius L, Dahleén G, Öhman A, Heyden G. 1981 Influence on periapical tissues in indigenous oral bacteria and necrotic pulp tissue in monkeys. Scand J Dent Res 89: 475–484. [PubMed: 6951246]

Molnar P. 2008 Dental wear and oral pathology: possible evidence and consequences of habitual use of teeth in a Swedish Neolithic sample. Am J Phys Anthropol 136: 423–431. [PubMed: 18383160]

Nair PNR, Pajarola G, Schroeder HE. 1996 Types and incidence of human periapical lesions obtained with extracted teeth. Oral Surg Oral Med Oral Pathol Oral Radiol Endod 81: 93–102. [PubMed: 8850492]

Nair RG, Samaranayake LP, Philipsen HP, Graham RG, Itthagarun A. 1996 Prevalence of oral lesions in a selected Vietnamese population. Int Dent J. 46: 48–51. [PubMed: 8744917]

Ohlrich EJ, Cullinan MP, Leichter JW. 2010 Diabetes, periodontitis, and the subgingival microbiota. J Oral Microbiol 2: 5818–5824

Omoregie FO, Ojo MA, Saheeb B, Odukoya O. 2011 Periapical granuloma associated with extracted teeth. Niger J Clin Pract 14: 293–296. [PubMed: 22037071]

Ogle OE. 2017 Odontogenic Infections. Dent Clin North Am 61: 235–252. [PubMed: 28317564]

Ottaviani G, Costantinides F, Perinetti G, Luzzati R, Contardo L, Visintini E, Tirelli G, Di Lenarda R, Gobbo M, Biasotto M. 2014 Epidemiology and variables involved in dental abscess: survey of dental emergency unit in Trieste. Oral Dis 20: 499–504. [PubMed: 23879656]

Pasternak-Júnior B, Teixeira CS, Silva-Sousa YT, Sousa-Neto MD. 2009 Diagnosis and treatment of odontogenic cutaneous sinus tracts of endodontic origin: three case studies. Int Endod J 42: 271–276. [PubMed: 19228218]

Pourdanesh F, Dehghani N, Azarsina M, Malekhosein Z. 2013 Pattern of odontogenic infections at a tertiary hospital in Tehran, Iran: a 10-year retrospective study of 310 patients. J Dent (Tehran) 10: 319–328. [PubMed: 24396351]

Pritzker KPH, Chateauvert J, Grynpas MD, Renlund RC, Turnquist JE, Kessler MJ. 1989 Rhesus macaques as an experimental model for degenerative arthritis. PR Health Sci J 8: 99–102.

Pritzker KPH, Kessler MJ. 2012 Arthritis, muscle, adipose tissue and bone diseases of nonhuman primates In: Abee CR, Mansfield K, Tardif SD, Morris T, editors. Nonhuman Primates in Biomedical Research: Volume 2, Diseases. San Diego: Elsevier-Academic Press P: 629–697.

Rothschild BM, Hong N, Turnquist JE. 1999 Skeletal survey of Cayo Santiago rhesus macaques: osteoarthritis and articular plate excrescences. Sem Athritis Rheumat 29: 100–111.

Rudney JD, Katz RV, and Brand JW. 1983 Interobserver reliability of methods for paleopathologial diagnosis of dental caries. Am J Phys Anthropol 62: 243–248. [PubMed: 6362425]

Ruquet M, Maille G, Tavitian P, Tardivo D, Hüe O, Bonfil JJ. 2016 Alveolar bone loss and ageing: possible association with coronary heart diseases and/or severe vascular diseases. Gerodontology 33: 356–362. [PubMed: 25395062]

Author Manuscript Author Manuscript Author Manuscript Author Manuscript

Sauther ML, Cuozzo FP, Sussman RW. 2001 Analysis of dentition of a living wild population of ring-tailed lemurs (Lemur catta) from Beza Mahafaly, Madagascar. Am J Phys Anthropol 114: 215–223. [PubMed: 11241187]

Sauther ML., Sussman RW, Cuozzo F. 2002 Dental and General Health in a Population of Wild Ring-Tailed Lemurs: A Life History Approach. Am J Phys Anthropol 117: 122–132. [PubMed: 11815947]

Shweta, Prakash SK. 2013 Dental abscess: A microbiological review. Dent Res J (Isfahan) 10: 585–591. [PubMed: 24348613]

Sindet-Pedersen S, Petersen JK, Götzsche PC. 1985 Incidence of pain conditions in dental practice in a Danish county. Community Dent Oral Epidemiol 13: 244–246. [PubMed: 3862509]

Stoner KE. 1995 Dental pathology in Pongo satyrus borneensis. Am J Phys Anthropol 98: 307–321. [PubMed: 8572155]

Streckfus CF, Baur U, Brown LJ, Bacal C, Metter J, Nick T. 1998 Effects of estrogen status and aging on salivary flow rates in healthy Caucasian women. Gerontology 44: 32–39. [PubMed: 9436013]

Turnquist JE, Cerroni AM, Faccia KJ, Boyd SK, Hallgrimsson B. 2012 Fragile Spines on Cayo Santiago: Bone mineral density, trabecular morphology and the potential for exploring the genetics of osteoporosis in rhesus monkeys In: Wang Q. editor. Bones, genetics, and behavior of Rhesus macaques: Macaca mulatta of Cayo Santiago and beyond. New York: Springer p 85–116.

Vier FV, Figueiredo JA. 2002 Prevalence of different periapical lesions associated with human teeth and their correlation with the presence and extension of apical external root resorption. Int J Endod 35: 710–719.

Wang Q. 2012 Dental maturity and the ontogeny of sex-based differences in the dentofacial complex of Rhesus macaques from Cayo Santiago In: Wang Q, editor. Bones, genetics, and behavior of Rhesus macaques: Macaca mulatta of Cayo Santiago and beyond. New York: Springer p 117–194.

Wang Q, Kessler MJ, Kensler TB, Dechow PC. 2016a The Mandibles of Castrated Male Rhesus Macaques (Macaca mulatta): The Effects of Orchidectomy on Bone and Teeth. Am J Phys Anthropol. 159:31–51. [PubMed: 26292999]

Wang Q, Turnquist JE, Kessler MJ. 2016b Free-ranging Cayo Santiago rhesus monkeys (Macaca mulatta): III. Dental eruption patterns and dental pathology. Am J Primatol 78: 127–142. [PubMed: 26118545]

Wang Q, Strait DS, Dechow PC. 2006a Fusion patterns of craniofacial sutures in rhesus monkey skulls of known age and sex from Cayo Santiago. Am J Phys Anthropol 131: 469–485. [PubMed: 16958075]

Wang Q, Opperman LA, Havill LM, Carlson DS, Dechow PC. 2006b Inheritance of sutural pattern at the pterion in rhesus monkey skulls. Ana Rec 288A: 1042–1049.

Wang Q, Dechow PC, Hens SM. 2007 Ontogeny and diachronic changes in sexual dimorphism in the craniofacial skeleton of rhesus macaques from Cayo Santiago, Puerto Rico. J Hum Evol 53: 350–361. [PubMed: 17645909]

Wiggs RB, Hall B. 2003 Nonhuman primate dentistry. Vet Clin North Am Exot Anim Pract 6: 661–687. [PubMed: 14534977]

Zachariades N, Vairaktaris E, Mezitis M, Rallis G, Kokkinis C, Moschos M. 2005 Orbital abscess: Visual loss following extraction of a tooth—Case report. Oral Surg Oral Med Oral Pathol Oral Radiol Endod 100: 70–73. [PubMed: 15953919]

Zappa UE, Polson AM, Eisenberg AD, Espeland MA. 1986 Microbial populations and active tissue destruction in experimental periodontitis. J Clin Periodontol 13: 117–125. [PubMed: 3455942]

Author Manuscript

Author Manuscript

Author Manuscript

Author Manuscript

Figure 1:

Apical abscesses induced by various kinds of causes in Cayo Santigao rhesus macaques. a-b. Apical abscesses. Specimen #2971 (a), Male, Age 29.12 years, Matriline 065. The apical abscess was induced by caries. Specimen #1600 (b), Male, Age 22.89 years, Matriline 114. Left two arrows pointed to apical abscess induced by wear in the first premolar, right two arrows pointed to apical abscess induced by fracture in the canine. Specimen #814 (c), Male, Age 10.2 years, Matriline 022. The apical abscess was induced by wear. Specimen #24 (d), Female, Age 10.29 years, Matriline 064. It was the youngest female with fistula in this study. The apical abscess was involved with AMTL. Specimen #448 (e), Male, Age 18.61 years, Matriline 119. The apical abscess was located at floor of the nasal cavity. Specimen #3048 (f), Male, Age 8.14 years, Matriline 065. It was the youngest male with fistula in this study. The apical abscess was involved with AMTL, which was located at the floor of the nasal cavity.

Author Manuscript

Author Manuscript

Author Manuscript

Author Manuscript

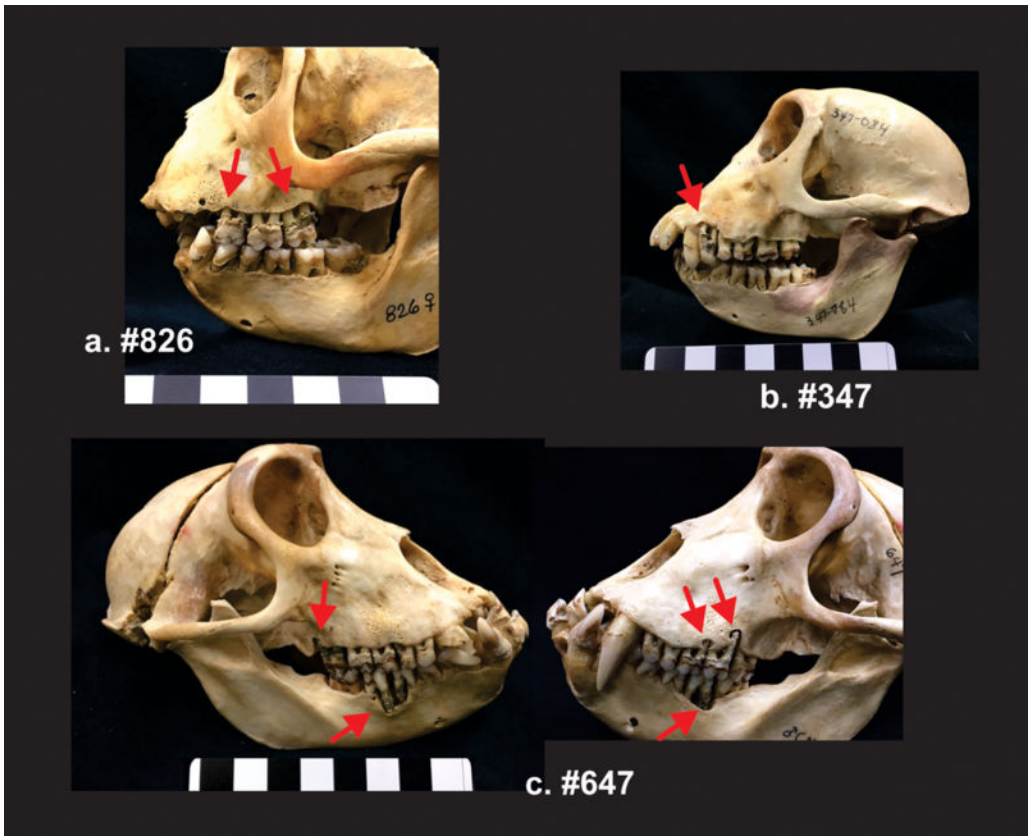

Figure 2:

Periodontal abscesses in Cayo Santigao rhesus macaques. Specimen #826 (a), Female, Age 24.8 years, Matriline 080. The typical periodontal abscess with two alveolar bone defect were more than 5mm but less than 10mm. Specimen #347 (b), F- Hysterectomized, Age 21.99 years, Matriline Unknown. Typical periodontal abscesses with alveolar bone defect were more than 10mm, expanding to the apex of the root. The root was covered with calculus deposition. Specimen #647 (c), Male-Castrated, Age 26.96 years, Matriline 076. Typical periodontal abscesses involved with several teeth, especially molars. At both sides, except for the up left arrows indicting the alveolar bone defect more than 5mm but less than 10mm, the other arrows indicated alveolar bone defect more than 10mm and obvious calculus deposition.

Author Manuscript

Author Manuscript

Author Manuscript

Author Manuscript

Figure 3:

Endodontic-periodontal combined abscesses in Cayo Santigao rhesus macaques. Specimen #2971 (a), Male, Age 29.12 years, Matriline 065. The buccal alveolar bone defect expanded to the apex of the root with calculus deposition on the root. Caries lesion was visible on the crown which led to the apical abscess. Specimen #2120 (b), Male, Age 28.30 years, Matriline 065. Buccal alveolar bone resorption expanded to the apex with calculus deposited on the root and around the cervical area. Caries and fissure were visible on crown which resulted in obvious apical abscess. Specimen #448 (c), Male, Age 18.61 years, Matriline 119. The upper arrow indicated the buccal alveolar bone lesion more than 5mm but less than 10mm and calculus deposited on the cervix. The Lower arrow indicated the apical abscess induced by serious wear on the crown. Two surface openings were connected by a channel underneath the cortical bone.

Author Manuscript

Author Manuscript

Author Manuscript

Author Manuscript

Figure 4:

Multiple and hidden abscesses. Specimen #782 (a), Male, Age 22.64 years, Matriline 128. It had fused fistula with four teeth was induced mainly by fracture resulting in pulp exposure. Specimen #304 (b), Male, Age 13.43 years, Matriline 081. In addition to abscesses in other areas, there was an apical abscess hidden under chin. Specimen #256 (c), Male, Age 18.77 years, Matriline Unknown. There were seven fistulae from apical abscesses in one mouth which were induced by caries and fracture.

Author Manuscript Author Manuscript Author Manuscript Author Manuscript

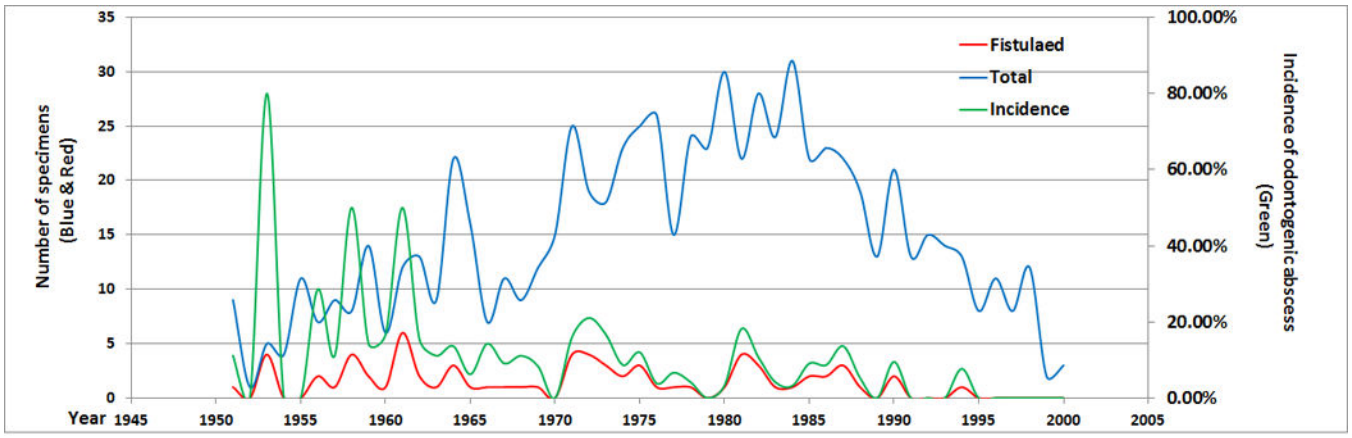

Figure 5:

Diachronic change of total specimen number, fistulated specimens, and incidence of fistulation for animals born between 1951 and 2000. Left Y-axis numbers of specimens (Blue line– Total; Red line– Fistulated); Right Y-axis percentage (Green line – Incidence of odontogenic abscesses/fistulae).

Author Manuscript Author Manuscript Author Manuscript Author Manuscript

Table 1

Composite of samples and prevalence of odontogenic abscesses

	N	Age (Years)	Individuals with Fistulae	Prevalence	Age Range of Fistulae
Male - Intact	283	8.01–31.44	53	18.73%	8.14–29.12
Female - Intact	460	8.05–29.12	15	3.26%	10.29–24.80
M-Castrated	4	10.29–26.96	1	25.00%	26.96
Intersex	3	15.24–22.05	2	66.67%	19.77–22.05
F-Hysterectomized	1	21.99	1	100.00%	21.99
F-Ovariectomized	1	29.26	0	0	-
Total	752	8.01–31.44	72	9.57%	8.14–26.96

Note: One intact male and two intact female specimens lacked either birth or death date. Age was estimated based on tooth wear.

Author Manuscript Author Manuscript Author Manuscript Author Manuscript

Table 2

Types of the fistulae lesions

Type	Apical abscess				Periodontal abscess		Endo-perio combined lesions	SUM
Number of lesions	Caries	Wear	Fracture	AMTL	5mm≤PD<10mm	PD≥10mm		
	48 (37.21%)	29 (22.48%)	27 (20.93%)	25 (19.38%)	30 (69.80%)	13 (30.20%)	20 (100%)	
Total	129 (67.19%)				43 (22.40%)		20 (10.42%)	192 (100%)

Author Manuscript Author Manuscript Author Manuscript Author Manuscript

Table 3

Distribution of teeth involved with fistulae

Tooth position		Number of Teeth with Fistulae	Apical abscess	Periodontal abscess	Endo-perio combined lesions
Incisors and Canines	Maxillary	76 (38.2%)	55	11	10
	Mandibular	69 (34.7%)	52	10	7
Anterior Summary		145 (72.9%)	107 (73.8%)	21 (14.5%)	17 (11.7%)
Premolars	Maxillary	9 (4.5%)	6	3	0
	Mandibular	25 (12.6%)	10	12	3
Molars	Maxillary	12 (6.0%)	0	11	1
	Mandibular	8 (4.0%)	2	6	0
Posterior Summary		54 (27.1%)	18 (33.3%)	32 (59.3%)	4 (7.4%)
Total		199 (100%)	125 (62.8%)	53 (26.6%)	21 (10.5%)

Author Manuscript Author Manuscript Author Manuscript Author Manuscript

Table 4

Incidence of specimens with fistulae in one-year age interval

	Male - Intact				Female - Intact				Other Specimens	
Age Interval (Yeas)	Total number of specimens	Fistulated specimens	% of fistulated specimens	% Cumulative (N=283)	Total number of specimens	Fistulated specimens	% of fistulated specimens	% Cumulative (N=460)	Total number of specimens	Fistulated specimens
8.00–8.99	30	1	3.33	0.35	57	0	0.00	0.00		
9.00–9.99	29	2	6.90	1.06	54	0	0.00	0.00		
10.00–10.99	25	2	8.00	1.77	47	1	2.13	0.22	1 (M-Castrated)	0
11.00–11.99	26	1	3.85	2.12	37	0	0.00	0.22	1 (M-Castrated)	0
12.00–12.99	25	2	8.00	2.83	29	0	0.00	0.22		
13.00–13.99	16	2	12.50	3.53	39	1	2.56	0.43		
14.00–14.99	17	2	11.76	4.24	36	0	0.00	0.43		
15.00–15.99	18	1	5.56	4.59	25	1	4.00	0.65	1 (Inersex)	0
16.00–16.99	10	2	20.00	5.30	24	0	0.00	0.65		
17.00–17.99	12	3	25.00	6.36	22	1	4.55	0.87		
18.00–18.99	17	8	47.06	9.19	18	1	5.56	1.09		
19.00–19.99	9	3	33.33	10.25	18	2	11.11	1.52	1 (Inersex)	1
20.00–20.99	12	7	58.33	12.72	16	2	12.50	1.96		
21.00–21.99	8	2	25.00	13.43	14	2	14.29	2.39	1(F-Hysterectomized)	1
22.00–22.99	12	6	50.00	15.55	6	1	16.67	2.61	1 (Intersex)	1
23.00–23.99	6	2	33.33	16.25	8	2	25.00	3.04		
24.00–24.99	3	1	33.33	16.61	3	1	33.33	3.26		
25.00–25.99	3	2	66.67	17.31	5	0	0.00	3.26		
26.00–26.99	3	2	66.67	18.02	0	0			2 (M-Castrated)	1
27.00–27.99	0	0			0	0				
28.00–28.99	1	1	100.00	18.37	1	0	0.00	3.26		
29.00–29.99	1	1	100.00	18.73	o	0			1(F-Ovariectomy)	0
30.00–30.99	0	0			0	0				
31.00–31.99	0	0			1	0	0.00	3.26		
SUM	283	53		18.73	460	15		3.26	9	4

Author Manuscript Author Manuscript Author Manuscript Author Manuscript

Table 5

Age distribution of specimens with fistulae (All specimens combined)

	Total	Age Intervals (Years)				
		8.00–11.99	12.00–15.99	16.00–19.99	20.00–23.99	>24.00
Sum of samples	752	307	206	131	84	24
Number of specimens with fistulae	72	7	9	21	26	9
Prevalence (%)	9.57%	2.28%	4.37%	16.03%	30.95%	37.50%
Male – Intact	283	110	76	48	38	11
Number of Male – Intact males with fistulae	53	6	7	16	17	7
Prevalence (%)	18.73%	5.45%	9.21%	33.33%	44.74%	63.64%
Female - Intact	460	195	129	82	44	10
Number of Female – Intact males with fistulae	15	1	2	4	7	1
Prevalence (%)	3.26%	0.05%	1.55%	4.88%	15.91%	10.00%
Others	9	2	1	1	2	3
Others with fistulae	4	0	0	1	2	1
Prevalence (%)	44.44%	0	0	100%	100%	33.3%

Author Manuscript Author Manuscript Author Manuscript Author Manuscript

Table 6

Demographics of fistulated specimens in matrilines with four or more family members older than 8 years in the skeletal collection. Family 092 (N=34. M17, F17) and Family 106 (N=8. M2,F6) had members no less than 4 yet no inflicted members in the collection.

Matriline	N	N of samples with fistulae (%)	N of observed samples		Average age (Age range)	N of samples with fistulae		Average age of fistulated specimens (Age range)	Numbers of fistulae lesions	Average number of fistulae lesions per affected specimens	Periapical abscess	Periodontal abscess	Endo-periodontal combined abscess
			Male	Female		Male	Female						
004	21	1(4.76%)	9	12	13.9 (8–23)	1	0	20.9	1	1.0	1	0	0
022	44	2(4.55%)	15	29	13.5 (8–23)	2	0	14.4(10–18)	4	2.0	3	0	1
031	51	4(7.84%)	12	39	13.2 (8–25)	3	1	18.3(13–25)	8	2.0	7	1	0
058	20	1(5.00%)	3	17	13.0 (8–26)	1	0	26.5	3	3.0	1	0	2
062	9	1(11.11%)	4	5	15.0 (8–23)	0	1	23.7	1	1.0	1	0	0
065	38	7(18.42%)	19	19	15.9 (8–31)	4	3	20.2 (8–29)	14	2.0	10	3	1
073	73	9(12.32%)	26	47	14.0 (8–26)	7	2	18.6 (12–25)	29	3.2	25	3	1
076	64	6(9.38%)	24+2 M-Castrated	38	15.9(8–28)	6	0	19.7(12–26)	22	3.7	12	6	4
081	6	2(33.33%)	4	2	14.9 (9–22)	2	0	17.8(13–22)	8	4.0	6	0	2
090	4	1(25.00%)	2	2	13.3(8–19)	1	0	13.5	3	3.0	2	0	1
091	71	5(13.73%)	29	42	13.6(8–22)	5	0	19.3(17–20)	11	2.2	7	3	1
22	27	2(7.41%)	10	17	15.4(18–25)	1	1	19.1(17–20)	3	1.5	3	0	0
116	88	9(10.23%)	32	56	14.7 (8–25)	7	2	20.6 (10–23)	27	3.0	16	8	3
AC	10	1(10.00%)	8	2	13.7(8–23)	1	0	9.8	1	1.0	1	0	0
DM	54	4(9.26%)	10	43+1F-Ovariectomized	14.8(8–29)	2	2	19.1(14–24)	7	1.8	1	5	1
RB	44	1(2.27%)	14	30	12.9(8–21)	1	0	20.8	4	4.0	2	2	0

Author Manuscript Author Manuscript Author Manuscript Author Manuscript

Table 7

Incidence of fistulated specimens in birth years and three 15-year-long periods: 1951–1965, 1966–1980, 1981–1995. The Period 1996–2000 was not included for comparison.

Year	Fistulated	Total	Incidence	Year	Fistulated	Total	Incidence	Year	Fistulated	Total	Incidence	Year	Fistulated	Total	Incidence
1951	1	9	11.1%	1966	1	7	14.3%	1981	4	22	18.2%	1996	0	11	0.0%
1952	0	1	0.0%	1967	1	11	9.1%	1982	3	28	10.7%	1997	0	8	0.0%
1953	4	5	80.0%	1968	1	9	11.1%	1983	1	24	4.2%	1998	0	12	0.0%
1954	0	4	0.0%	1969	1	12	8.3%	1984	1	31	3.2%	1999	0	2	0.0%
1955	0	11	0.0%	1970	0	15	0.0%	1985	2	22	9.1%	2000	0	3	0.0%
1956	2	7	28.6%	1971	4	25	16.0%	1986	2	23	8.7%				
1957	1	9	11.1%	1972	4	19	21.1%	1987	3	22	13.6%				
1958	4	8	50.0%	1973	3	18	16.7%	1988	1	19	5.3%				
1959	2	14	20.0%	1974	2	23	8.7%	1989	0	13	0.0%				
1960	1	6	16.7%	1975	3	25	12.0%	1990	2	21	9.5%				
1961	6	12	50.0%	1976	1	26	3.8%	1991	0	13	0.0%				
1962	2	13	15.4%	1977	1	15	6.7%	1992	0	15	0.0%				
1963	1	9	11.1%	1978	1	24	4.2%	1993	0	14	0.0%				
1964	3	22	13.6%	1979	0	23	0.0%	1994	1	13	7.7%				
1965	1	16	6.3%	1980	1	30	3.3%	1995	0	8	0.0%				
1951–1965	28	146	19.2%	1966–1980	24	282	8.5%	1981–1995	20	288	6.9%	1996–2000	0	36	0.00%
	Age Range 10.29–26.96 Mean:19.83 SD: 4.70	Age Range 8.03–31.44 Mean:15.23 SD: 5.52			Age Range 9.00–29.12 Mean:19.64 SD: 4.97	Age Range 8.01–28.95 Mean:14.43 SD:4.63			Age Range 8.14–25.52 Mean:18.77 SD: 4.41	Age Range: 8.03–24.39 Mean:13.89 SD: 4.30				Age: Range 8.13–13.90 Mean: 9.71 SD:1.36	

Am J Phys Anthropol. Author manuscript; available in PMC 2019 September 27.

Author Manuscript Author Manuscript Author Manuscript Author Manuscript

Table 8

Epidemiology of odontogenic abscesses in rhesus macaques age 8 years old and above from Cayo Santiago born between 1951 and 2000

	Note
Prevalence	Overall prevalence is 9.57%
Age	The level of incidence is age-dependent. The prevalence is lower for below age 16 years than for age 16 and above (3.1% vs. 23.4%).
Sex	Prevalence is significantly higher in intact males (18.7%) than in intact females (3.3%). Other sexes have high incidence in old animals as well.
Lesion types	The fistulae mainly came from apical disease (66.2%), periodontal disease (22.4%) and EPC lesions (10.4%). The prevalence of periapical abscesses was significantly higher than periodontal abscesses and EPC lesions
Inflicted teeth	Anterior teeth (incisors and canines) are more inflicted than posterior teeth premolars and molars (72.9% vs. 27.1%). Among fistulated anterior teeth, 73.8% are periapical, while among fistulated posterior teeth, nearly 60% are periodontal abscess. The rates of infliction is comparable between maxillary and mandibular teeth, expect for premolars (Maxillary vs. Mandibular : 4.5% vs. 12.1%).
Causes	Caries, wear, fracture, periodontal diseases, endodontic diseases, etc.
Diachronic trend	Animals born in the early period (1951–1965) had significantly higher percentage inflicted by abscesses than later periods (1966–1980 and 1981–1995).
Family history	Some matrilineal families have high prevalence of odontogenic abscesses, such as Families 065 (18.42%), 073 (12.32%),091 (13.73%), and 116 (10.23%). Some families such as Family 092 have no inflicted members.
Consequences	ATML, alveolar bone resorption. Lesion may spread to adjacent tissues, sinus, orbits, deep fascial spaces of the neck, even intracranial cavity, and thoracic cavity, resulting in a significant increase in the animals' morbidity and mortality
Risk	Age, low sex steroids, diet, ecological condition, oral hygiene, survival and adaptation stresses, and possible genetic predisposition

Author Manuscript Author Manuscript Author Manuscript Author Manuscript

Table 9

Variations in prevalence of odontogenic abscesses in primates, humans and other animals

Samples	Sample size	Location	Dental abscess prevalence	Periapical abscess	Periodontal abscess	Reference
Rhesus macaques (*Macaca mulatta*)	752	Cayo Santiago	9.57%			This study
Mountain gorillas	31	Central Virungas		12.9%	32.3%	Lovell, 1990a
Chimpanzees	10	Gombe National Park, Tanzania		50%	≈80%	Kilgore, 1989
Ring-tailed lemur (*Lemur catta*)	42	Beza Mahafaly Reserve, in Southern Madagascar	19.05%	75%	25%	Sauther et al., 2002
Howler monkey, (*Allot&z carayu*)	65				1.5–15%	Hall et al., 1967
Orangutan	223	Selenka 1892 to 1896 from wild-shot specimens in West Borneo		2–26% (young-old)	2–23% (young-old)	Stoner, 1995
Ring-tailed lemur (*Lemur catta*)			14%			Lovell, 1991
Old World monkeys			3–15%			Lovell, 1991
New World monkey			8–34%			Lovell, 1991
Chimpanzees	37			32.4%	8.11%	Lovell, 1991
Gorilla	75			42.67%	56%	Lovell, 1991
Orangutan	28			21.4%	10.71%	Lovell, 1991
Feline (cat)	265	U.S.A.		13.21%		Lommer, 2000
Human	824 children	Nigeria	6.4%			Azodo, 2012
Human	708 older people at care homes	Wales	10–27%			Karki, 2015
Human	5,467 periodontal patients	U.S.A.			1.04%	Gray, 1994
Human		U.S.A.			14%	Ahl, 1986
Human		Spain			8%	Galego-Feal et al., 1996
Human	550 Vietnamese living in Hong Kong	Vietnam		36%		Nair,1996
Human	600 dentists	UK		5% (AAA).	6–7‰	Lewis, 1989
Human	35,464 patients 17–70 year-old	Demark		31% (AAA)		Sindet-Pedersen ,1985
Human	2,308 cases	United States		11.1%		Bhaskar,1996.

Author Manuscript Author Manuscript Author Manuscript Author Manuscript

Samples	Sample size	Location	Dental abscess prevalence	Periapical abscess	Periodontal abscess	Reference
Human	20–81-year-old. N=4310	Pomerania, Germany			17.6% Severe periodontitis(CDC classification)	Holtfrete et al.,2009
Human	adult /107	Canada			22.4%(Severe periodontitis)	Brothwell et al., 2009
Human	24,000	Trieste, Italy	2.87%			Ottaviani, 2014
Human	4 to 22 years with vitamin D-resistant rickets. N=24	United States	100% (25% onset in primary dentition)			McWhorter, 1991
Human	322 residents of the Porto area, aged 30–39 years.	Portugal		27% AP		Marques, 1998

Abbreviation: AAA - Acute apical abscesses; CDC - Centers for Diseases Control and Prevention; AP - Apical periodontitis. Severe periodontitis was characterized as presence of ≥ 2 interproximal sites with ≥ 6 mm clinical attachment loss, not on the same tooth and presence of ≥ 1 interproximal sites with a ≥ 5 mm probing depth.