

University of Kentucky

UKnowledge

---

Otolaryngology--Head & Neck Surgery Faculty  
Publications

Otolaryngology--Head & Neck Surgery

---

12-5-2020

## Congenital Nasal Pyriform Aperture Stenosis Repair: A Case Series and Discussion of Postoperative Care

Harper L. Wilson

*University of Kentucky, Harper.wilson@uky.edu*

Nicholas Van Maele

*University of Kentucky, Nicholas.vanmaele@uky.edu*

Kenneth C. Iverson

*University of Kentucky, Kenneth.iverson@uky.edu*

Follow this and additional works at: [https://uknowledge.uky.edu/otolaryngology\\_facpub](https://uknowledge.uky.edu/otolaryngology_facpub)



Part of the [Otolaryngology Commons](#), and the [Surgery Commons](#)

**Right click to open a feedback form in a new tab to let us know how this document benefits you.**

---

### Repository Citation

Wilson, Harper L.; Van Maele, Nicholas; and Iverson, Kenneth C., "Congenital Nasal Pyriform Aperture Stenosis Repair: A Case Series and Discussion of Postoperative Care" (2020). *Otolaryngology--Head & Neck Surgery Faculty Publications*. 12.

[https://uknowledge.uky.edu/otolaryngology\\_facpub/12](https://uknowledge.uky.edu/otolaryngology_facpub/12)

This Article is brought to you for free and open access by the Otolaryngology--Head & Neck Surgery at UKnowledge. It has been accepted for inclusion in Otolaryngology--Head & Neck Surgery Faculty Publications by an authorized administrator of UKnowledge. For more information, please contact [UKnowledge@lsv.uky.edu](mailto:UKnowledge@lsv.uky.edu).

---

## Congenital Nasal Pyriform Aperture Stenosis Repair: A Case Series and Discussion of Postoperative Care

Digital Object Identifier (DOI)


<https://doi.org/10.1016/j.xocr.2020.100247>

### Notes/Citation Information

Published in *Otolaryngology Case Reports*, v. 18, 100247.

© 2020 Elsevier Inc.

This is an open access article under the CC BY-NC-ND license (<https://creativecommons.org/licenses/by-nc-nd/4.0/>).



# Congenital nasal pyriform aperture stenosis repair: A case series and discussion of postoperative care

H.L. Wilson, N. Van Maele, K.C. Iverson<sup>\*</sup>

University of Kentucky Medical Center, 800 Rose Street, Lexington, KY, 40536, USA

## ARTICLE INFO

### Keywords:

Pediatric Airway  
Pyriform aperture  
Craniofacial

## ABSTRACT

Congenital nasal pyriform aperture stenosis (CNPAS) is a rare condition related to holoprosencephaly in which bony overgrowth of the medial nasal process of the maxilla narrows the pyriform aperture. CNPAS presents in neonates with signs of upper airway obstruction ranging from mild to severe respiratory distress and failure to thrive. Surgical intervention is indicated after failed conservative measures and generally includes temporary stent placement. We report a series of 3 cases of CNPAS treated surgically, examine postoperative care recommendations in the literature, and present a comprehensive postoperative care regimen with a novel method to maintain stent patency.

## 1. Case series

### 1.1. Case 1

Patient 1 was a 3670-g term male born via caesarian section due to failure to progress. He required CPAP briefly after delivery, was transitioned to 8L of high flow oxygen, and was transferred to a tertiary care NICU.

There was difficulty passing a 5fr NG tube into the nares, prompting a flexible fiberoptic nasal endoscopy that revealed bilateral narrowing of the anterior nasal cavities without choanal atresia. A narrowed palate with central maxillary alveolar papilla was noted suggesting a pre-erupted solitary median maxillary central incisor (SMMCI). A neonatal rhinitis protocol was initiated [1] and a CT sinus revealed a SMMCI, 6mm pyriform aperture (PA) width, and inward bowing of the nasal processes of the maxilla. MRI, endocrine evaluation, and genetics consultations were performed with no abnormal findings.

The patient was taken to the OR on day 6 of life for a sublabial approach to drill out the pyriform aperture to a width of 12mm with subsequent nasal dilation and nasal turbinate out fracture. Size 3.5 endotracheal (ET) tube stents were placed bilaterally to 5cm depth and secured around the posterior septum with a suture bridle and anterior ET tube spacer.

The proposed postoperative protocol was followed with inpatient pediatric oxyhood utilization [Figs. 1–2]. The patient was discharged from the NICU on POD 10 and weaned from nasal saline and anterior

suctioning after 3 weeks. No postoperative septal damage or synechiae were noted.

### 1.2. Case 2

Patient 2 was a 3630-g term female infant born via NSVD with mild midface hypoplasia noted at birth. She was transferred to a tertiary care NICU on day 10 of life for continued mild/moderate work of breathing, CPAP dependence, and failure of a neonatal rhinitis protocol.

Flexible fiberoptic laryngoscopy exam demonstrated hypertrophic mucosa and narrowing in the bilateral anterior nares without choanal atresia. A papilla was also noted on the anterior medial maxillary alveolar ridge suggestive of a SMMCI. CT confirmed a PA width of 3.5mm at the level of the hard palate, no choanal atresia, and a SMMCI. The endocrinology team was consulted, noted adrenal suppression, and recommended judicious use of the dexamethasone nasal drops. Ophthalmology was consulted for optic nerve hypoplasia. A follow up MRI Brain was ordered and demonstrated an essentially normal brain with mildly large prepontine cistern and mild posterior angulation of the brainstem thought to be developmental.

Due to failure to wean from CPAP with medical management, the patient was taken to the OR on day 19 of life for sublabial drill out and repair of CNPAS to a PA width of 15mm, bilateral dilatory inferior turbinate outfracture, and placement of 3.5 ET tube stents with a bridle.

The proposed postoperative protocol was followed with inpatient pediatric oxyhood utilization until discharge on POD 14 [Figs. 1–2]. At

<sup>\*</sup> Corresponding author. University of Kentucky Medical Center, Department of General Surgery, 800 Rose Street, Lexington, KY, 40536, USA.

E-mail addresses: [Harper.wilson@uky.edu](mailto:Harper.wilson@uky.edu) (H.L. Wilson), [Nicholas.vanmaele@uky.edu](mailto:Nicholas.vanmaele@uky.edu) (N. Van Maele), [Kenneth.iverson@uky.edu](mailto:Kenneth.iverson@uky.edu) (K.C. Iverson).

follow-up 1 week after discharge she was doing well with adequate oral intake and weight gain despite not using nasal saline daily. Crusting was suctioned in the clinic and saline was reinstituted. One month after discharge she had a URI with some increased work of breathing which resolved within 24 hours after initiating a 1-week rhinitis protocol. No postoperative septal damage or synechiae were noted.

### 1.3. Case 3

Patient 3 was a 2160-g premature female born at 35 3/7 weeks via emergent caesarian section due to decelerations, non-reassuring heart tones, and premature rupture of membranes. She received positive pressure ventilation after birth with APGARs of 1 and 7 but was able to be transitioned to room air. A 6fr catheter was could not be passed through the nares bilaterally and she suffered repeated desaturations

<b>POD 0-1</b>	<b>Airway</b>	- Return from OR to NICU intubated - Plans to extubate/wean on POD1
	<b>Nasal Saline</b>	- 3-4 drops in each stent Q2H
	<b>Suction</b>	- Performed by nursing staff following NS drops - Measured to predetermined depth using 6/8Fr catheter - Depth = intraoperative stent length + 1cm
	<b>Nasal Steroids</b>	- Dexamethasone ophthalmic 0.1% solution - 1 drop in each stent + 1 drop around each stent Q12H
	<b>IV Antibiotics</b>	- Ampicillin or Cefazolin for 1 week
<b>POD 1</b>	<b>Airway</b>	- Spontaneous breathing trial and extubation appropriateness assessment by NICU team - Vigorous NS lavage and suctioning of each stent by ENT team to ensure pre-extubation stent patency - Placement in oxyhood following extubation with O2 titrated to 21% as tolerated
	<b>Nasal Saline</b>	- Continue Q2H as above
	<b>Suction</b>	- Continue following NS drops as above
	<b>Nasal Steroids</b>	- Continue dexamethasone drops Q12H as above
	<b>Nutrition</b>	- Allow infant to initiate oral feeds as tolerated
<b>POD 2-4</b>	<b>Airway</b>	- Continuous oxyhood use except for oral feedings
	<b>Nasal Saline</b>	- Decrease to Q3H with nasal checks
	<b>Suction</b>	- Decrease to Q3H following NS drops
	<b>Nasal Steroids</b>	- Continue dexamethasone drops Q12H as above
<b>POD 5-7</b>	<b>Airway</b>	- Bedside stent removal by Otolaryngology team with simple release of the bridle suture/tie with saline lavage and deep suctioning - Continue oxyhood for 48 hours post stent removal
	<b>Nasal Saline</b>	- Continue at Q3H with nasal checks
	<b>Suction</b>	- Neo or bulb suction anteriorly (avoid deep suction) Q3H following NS drops
	<b>Nasal Steroids</b>	- 2 Dexamethasone drops per nostril Q12H for 7 days post-stenting with subsequent taper if clinically desired
<b>Discharge</b>	<b>Airway</b>	- Off oxyhood for 48 hours maintaining airway with Q3H NS drops and anterior suctioning
	<b>Nutrition</b>	- Tolerating oral feeds
	<b>Other</b>	- Stable from NICU standpoint

Fig. 1. Postoperative care protocol.

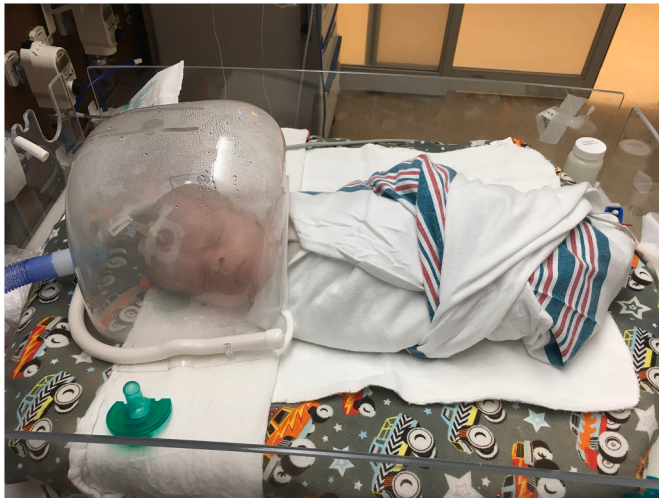

Fig. 2. Postoperative oxyhood setup.

under non-invasive ventilation requiring intubation and transfer to a tertiary care NICU for definitive care.

Pediatric otolaryngology was consulted for respiratory distress and concern for choanal atresia. A 2.5fr NG catheter was passed bilaterally and a narrowed palate with a central maxillary papilla suggesting a pre-ruptured SMMCI was noted. CT sinus confirmed a SMMCI, PA width of 3.3mm, and no choanal atresia. An MRI brain was ordered and came back normal. Endocrine evaluation took place with normal pituitary lab work. The genetics team was consulted, and a chromosome 15 microduplication known to be associated with slower growth and some developmental delay was discovered. Ophthalmology was consulted for concern for optic nerve hypoplasia on exam.

She was taken to the OR on day 7 of life due to inability to tolerate extubation for sublabial repair and drill out of the CNPAS to 12mm, bilateral inferior turbinate dilatory outfracture, and placement of 4cm 3.0 ET tube stents with a bridle.

The patient was discharged on POD 9 after following the postoperative protocol with oxyhood utilization [Figs. 1–2]. On follow-up, she was weaned to PRN nasal saline and had appropriate oral intake and growth respective to her genetic condition. No postoperative septal damage or synechiae were noted.

## 2. Discussion

### 2.1. Background

The first clinical cases of CNPAS were described in 1989 [2]. CNPAS is a rare developmental anomaly in which the pyriform aperture is narrowed due to bony overgrowth of the nasal process of the maxilla [3]. It may present as an isolated abnormality or in combination with others including thyroid dysgenesis, holoprosencephaly, and in 60% of cases a SMMCI [4]. CNPAS presents soon after birth with non-specific symptoms of upper airway obstruction including problems with feeding, cyanotic episodes, apnea relieved by crying, and potentially severe respiratory distress [5]. A diagnosis of CNPAS is suggested by an inability to pass a 5/6 Fr catheter through the pyriform aperture bilaterally and confirmed by a PA width <11mm on CT [6,7]. The differential diagnosis includes bilateral choanal atresia, which presents similarly and is confirmed by an inability to pass an NG tube into the nasopharynx as well as endoscopic and radiographic visualization of the atresia [2].

### 2.2. Management

Management of CNPAS is initially conservative with a combination of nasal saline administration, nasal steroids, and/or topical

decongestants and temporary use of McGovern nipples or oropharyngeal airways for severe respiratory symptoms [4,8,9]. No objective operative criteria have been formally established, but surgery is generally performed when severe respiratory distress develops or after 2 weeks of failed conservative management [5,8].

The most recognized surgical technique of CNPAS involves a sublabial approach to widen the pyriform aperture by drilling a portion of the maxillary bony overgrowth, followed by bilateral nasal stenting with ET tubes [2,10]. Other surgical approaches have been described including dilation and rapid maxillary expansion [11–13], but no secondary occurrence has been described in the literature when the standard surgical intervention is performed sufficiently [4,5].

### 2.3. Surgical technique

At our institution, the operative protocol is as follows. The mucosa of upper lip is anesthetized with 0.5% lidocaine with 1:200,000 epinephrine and monopolar cautery is used to incise through the upper lip mucosa leaving a 5mm cuff of unattached gingiva to allow for closure. Dissection is carried down to the level of the maxilla and the periosteum is elevated to expose the pyriform aperture. Bilateral relaxing incisions are made in the soft tissue along the pyriform aperture preserving the neurovascular bundles and a 2 mm diamond bur is used to widen the pyriform aperture laterally and posteriorly to the level of the inferior turbinate insertion with care taken to avoid the nasolacrimal duct. An 18-French ureteral sound dilator is then passed through each nasal cavity resulting in complete inferior turbinate outfracture to the choanae. A 0-degree pediatric nasal endoscope is used for close inspection, the nasal cavity is irrigated, and customized lengths of 3.5 ET tubes are placed bilaterally to the level of the choanae (typically 4–5cm). Of note, 3.0 tubes were utilized in one preterm infant secondary to her small size. A 3–0 nylon suture is passed medial to the stents and around the posterior septum to bridle the stents in place. Anteriorly, a third 1cm piece of ET tube is placed to bridge the stents, hold the bridle, and protect the columella [Fig. 3]. At this time, an 8 French suction catheter should be tested for easy passage through each stent when using 3.5 ET tubes. The sublabial incision is closed in an interrupted fashion and the stents are secured. Our described post-operative protocol is then followed.

### 2.4. Postoperative Care Protocol

In Fig. 1, we present a detailed protocol for postoperative care in CNPAS repair. We plan for extubation on POD1 within the NICU with the ENT team present and several pre-extubation measures taken to ensure stent patency. Regular nasal saline washes and suctioning of stents is performed by nursing staff with instructions to suction only 1cm past the posterior end of the stents to prevent nasopharyngeal trauma. Nasal steroid drops are employed to prevent excess granulation tissue formation. Oral feedings are initiated as tolerated as early as POD 1. We also employ a pediatric oxygen hood (oxyhood) until at least POD 5 to provide constant, robust humidification of inspired air. The oxyhood is a transparent plastic enclosure that surrounds an infant's head and provides continuous humidification of inspired air. Stent removal is performed at bedside without anesthesia as early as POD 5 by cutting the exposed anterior knot of the suture to relieve the retroseptal tension holding the stents in place.

### 2.5. Literature review of stenting methods and postoperative care

Controversy exists in the literature regarding the type, duration, and method of securing stents in CNPAS repair and even whether stents should be utilized at all. Most publications endorse the use of 2.5–3.5mm ET tubes for stenting, but some utilized silicon tubing [Fig. 4]. Early research suggested that stents should be placed for a minimum of 5 days to prevent restenosis and allow lifted mucosa to reattach to the bony margins, but no more than 15 days to avoid mucosal



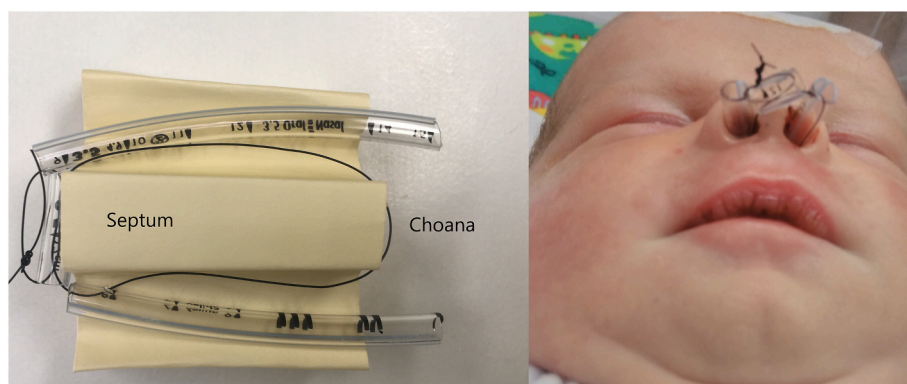

Fig. 3. Endotracheal tube bridge with retroseptal, extraluminal suture.

Year and Reference	Stent Details				Postoperative Care									
	Fixation		Type		Duration	During Stenting					Post-Stent			
	Columellar Suture	Retroseptal Suture	ET Tube	Silicone Tube	Days Stented	Topical Steroids	Saline	Decongestants	Suction	Antibiotics	Humidification	Topical Steroids	Saline	Decongestants
1989 [2]			X		14-28									
2001 [4]	X		X		5-15							X		X
2002 [3]	X			X	5-7		X		X	X			X	X
2002 [26]				X	6-7				X					
2003 [18]			X		14-28									
2009 [14]	X		X		7-10	X		X	X		X			
2010 [23]			X		28									
2012 [25]			X		< 28	X		X						
2012 [27]				X	14		X	X					X	X
2013 [28]			X		10		X		X	X			X	
2014 [24]			X		21-28	X		X						
2014 [15]				X	10			X						X
2015 [8]		X	X		14-28		X	X						
2015 [29]	X		X		7									
2017 [17]			X		n/s		X		X			X	X	X
2018 [10]	X		X		5-28	X	X		X	X				

Fig. 4. Postoperative care chronological literature review [14–17].

necrosis [4]. Publications generally endorse stent placement for 5–28 days depending on the degrees of initial stenosis and mucosal dissection during surgery [2] [Fig. 4].

The predominant method of securing stents to the columella using nonabsorbable sutures is associated with complications of synechia, nasal alar or columellar necrosis, granulation tissue formation, and septal ulcerations [10,18,19]. In one study, 24% of patients developed septal ulcerations secondary to transcolumellar sutures during 7–10 days of stenting [18]. In an alternative stenting technique adapted from choanal atresia repair, an ET tube is bent into a U shape, cut halfway through the diameter posteriorly at the bend to create patency, and placed transorally with the bend sitting behind the posterior septum and the ends of the tube protruding from the nares [20]. This method reduces the risk for septal perforation but requires an additional operation with general anesthesia to remove the stent transorally [20].

To improve the understanding of postoperative care in CNPAS repair, we performed an in-depth analysis of postoperative care in 16 publications in which surgical repair of CNPAS was performed with ET tube or silastic tube nasal stent placement [Fig. 4]. The method of stent fixation, type of stent, duration of stenting, types of postoperative care during stenting, and postoperative care following stent removal are detailed in chronological order of publication in Fig. 4.

## 2.6. Addressing current challenges in postoperative care

There appears to be a significant variation and ambiguity of stenting methods and post-operative regimens in CNPAS literature. This controversy likely stems from the inherent difficulty of trying to maintain stent and thus airway patency postoperatively secondary to crust formation and obstruction of the non-biological lumen, requiring significant effort and attention for postoperative care givers. It was this challenge that led to the development of the authors' technique and protocol to maintain the advantages that a stent affords for maintaining surgical patency while also improving upon challenges and frustrations inherent to the stents. Considering this, our group is eager to present a detailed regimen that has been successfully employed in this case series with the stenting method utilized.

We present a method of securing stents in place with several advantages to the standard of columellar suturing. The use of an anterior ET tube bridge between the stents reduces pressure on the columella, decreases patient discomfort, and has prevented any columellar necrosis, intranasal synechia, or septal perforations in our patients [Fig. 3] [10]. Running the retroseptal anchoring suture medial to the stents rather than within them avoids introducing a nidus for crust formation and obstruction within the stents [Fig. 3] [21]. The authors' method also ensures that stent removal can be performed at bedside without anesthesia by cutting the exposed anterior knot of the suture, while several publications require an additional trip to the OR to remove stents secured in place by columellar sutures [3,18,22]. Risk of intraoperative hypoxemia increases with younger age and neonates with CNPAS may be syndromic or have additional medical problems that complicate anesthesia [23]. Avoiding additional anesthesia during stent removal benefits patient safety, minimizes healthcare costs, and alleviates difficulties with scheduling in the postoperative window [23].

We designed our postoperative regimen to ensure a safe yet expeditious recovery by preventing postoperative issues common in our previous experience but rarely addressed in literature: crusting and stent obstruction [2,24]. Teaching parents how to perform proper irrigation and suctioning of stents may be difficult, and parents may not be able to recognize dangerous stent obstruction and reach the hospital in time for an intervention [11,13]. Stent obstruction can occur rapidly, and was the likely cause of postoperative death in one reported case [25]. We recommend that patients remain in the hospital while stented to allow nasal irrigation, nasal steroid administration, and suctioning of stents to be performed by Otolaryngology or nursing staff to prevent crusting and dangerous stent obstruction.

Use of the pediatric oxyhood is also recommended because it maintains stent patency with relative ease of use by offering unmatched airway humidification without the risk of displacing stents or being pulled off by the neonate. Nasal cannulas and masks require fixation to the neonate and therefore cannot be used effectively following CNPAS repair [26] [Fig. 2]. Length of stenting is highly debated in literature, some publications recommending up to 28 days [2,8,10,22,27–29]. With use of this rigorous postoperative care regimen, we recommend stent removal as soon as POD 5 with an additional 48 hours of inpatient observation before discharge to ensure that restenosis and mucosal dehiscence do not occur.

## 3. Conclusion

Surgical intervention for CNPAS has been described in literature for nearly 32 years, but the techniques for stent placement and postoperative care have not reached a consensus as described in the literature survey. We describe our postoperative protocol following the most described operative technique for the surgical repair of CNPAS. This includes a method of stent securement that reduces complications while providing clear advantages against the current standard of columellar suturing. In addition, we present a detailed postoperative care regimen with the use of the pediatric oxyhood to maintain stent patency.

## Declaration of competing interest

There are no conflicts of interest to disclose.

## References

- [1] Nathan CAO, Seid AB. Neonatal rhinitis. *Int J Pediatr Otorhinolaryngol* 1997;39(1):59–65. [https://doi.org/10.1016/S0165-5876\(96\)01464-4](https://doi.org/10.1016/S0165-5876(96)01464-4).
- [2] Brown Orval E, Myer Charles M, Manning SC. Congenital nasal pyriform aperture stenosis. *Laryngoscope* 1989;(January):86–91.
- [3] Losken A, Burstein F, Williams J. Congenital nasal pyriform aperture stenosis: diagnosis and treatment. *Plast Reconstr Surg* 2002;109(5):1506–11.
- [4] Van Den Abbeele T, Triglia JM, Francois M, Narcy P. Congenital nasal pyriform aperture stenosis: diagnosis and management of 20 cases. *Ann Otol Rhinol Laryngol* 2001;110:70–5.
- [5] Wormald R, Hinton-Bayre A, Bumbak P, Vijayasekaran S. Congenital nasal pyriform aperture stenosis 5.7mm or less is associated with surgical intervention: a pooled case series. *Int J Pediatr Otorhinolaryngol* 2015;79(11):1802–5. <https://doi.org/10.1016/j.ijporl.2015.07.026>.
- [6] Hui Y, Friedberg J, Crysdale WS. Congenital nasal pyriform aperture stenosis as a presenting feature of holoprosencephaly. *Int J Pediatr Otorhinolaryngol* 1995;31(2–3):263–74. [https://doi.org/10.1016/0165-5876\(94\)01096-G](https://doi.org/10.1016/0165-5876(94)01096-G).
- [7] Belden CJ, Mancuso AA, Schmalfuss IM. CT features of congenital nasal pyriform aperture stenosis: initial experience. *Radiology* 1999;213(2):495–501. <https://doi.org/10.1148/radiology.213.2.r99oc38495>.
- [8] Moreddu E, Le Treut-Gay C, Triglia JM, Nicollas R. Congenital nasal pyriform aperture stenosis: elaboration of a management algorithm from 25 years of experience. *Int J Pediatr Otorhinolaryngol* 2016;83:7–11. <https://doi.org/10.1016/j.ijporl.2016.01.011>.
- [9] Collins B, Powitzky R, Enix J, Digoy GP. Congenital nasal pyriform aperture stenosis: conservative management. *Ann Otol Rhinol Laryngol* 2013;122(10):601–4. <https://doi.org/10.1177/000348941312201001>.
- [10] Castaño JE, Chi DH. Pyriform aperture stenosis repair in infants. *Oper Tech Otolaryngol - Head Neck Surg* 2018;29(2):51–4. <https://doi.org/10.1016/j.otot.2018.03.003>.
- [11] Wine TM, Dedhia K, Chi DH. Congenital nasal pyriform aperture stenosis: is there a role for nasal dilation? *JAMA Otolaryngol - Head Neck Surg* 2014;140(4):352–6. <https://doi.org/10.1001/jamaoto.2014.53>.
- [12] Collares MVM, Tovo AHS, Duarte DW, Schweiger C, Fraga MM. Novel treatment of neonates with congenital nasal pyriform aperture stenosis. *Laryngoscope* 2015;125(12):2816–9. <https://doi.org/10.1002/lary.25198>.
- [13] Bazak R, Ibrahim AA, Hussein WKA, Abdelnaby MM, Elwany S. Extramucosal pyriplasty without stenting for management of pyriform aperture stenosis. *Eur Arch Oto-Rhino-Laryngology* 2018;275(6):1469–75. <https://doi.org/10.1007/s00405-018-4969-5>.
- [14] Lee KS, Yang CC, Huang JK, Chen YC, Chang KC. Congenital pyriform aperture stenosis: surgery and evaluation with three-dimensional computed tomography. *Laryngoscope* 2002;112(5):918–21. <https://doi.org/10.1097/00005537-200205000-00025>.
- [15] Sesenna E, Leporati M, Brevi B, Oretti G, Ferri A. Congenital nasal pyriform aperture stenosis: diagnosis and management. *Ital J Pediatr* 2012;38(1):1–5. <https://doi.org/10.1186/1824-7288-38-28>.

- [16] AbdollahiFakhim S, Bayazian G, Ghanbarpour E, Badebarin D. Congenital nasal pyriform aperture stenosis: the report of four rare cases. *Egypt J Ear, Nose, Throat Allied Sci* 2013;14(3):213–6. <https://doi.org/10.1016/j.ejenta.2013.08.003>.
- [17] Gonik NJ, Cheng J, Lesser M, Shikowitz MJ, Smith LP. Patient selection in congenital pyriform aperture stenosis repair - 14 year experience and systematic review of literature. *Int J Pediatr Otorhinolaryngol* 2015;79(2):235–9. <https://doi.org/10.1016/j.ijporl.2014.12.016>.
- [18] Devambez M, Delattre A, Fayoux P. Congenital nasal pyriform aperture stenosis: diagnosis and management. *Cleft Palate-Craniofacial J* 2009;46(3):262–7. <https://doi.org/10.1597/07-182.1>.
- [19] Günther L, Sari-Rieger A, Jablonka K, Rustemeyer J. Clinical course and implications of congenital nasal pyriform stenosis and solitary median maxillary central incisor in a newborn: a case report. *J Med Case Rep* 2014;8(1):1–5. <https://doi.org/10.1186/1752-1947-8-215>.
- [20] Newman JR, Harmon P, Shirley WP, Hill JS, Woolley AL, Wiatrak BJ. Operative management of choanal atresia a 15-year experience. *JAMA Otolaryngol - Head Neck Surg* 2013;139(1):71–5. <https://doi.org/10.1001/jamaoto.2013.1111>.
- [21] Wood J, Van Der Meer G. *Surgery for congenital nasal pyriform aperture stenosis. CNPAS*.; 2008.
- [22] Shikowitz MJ. Congenital nasal pyriform aperture stenosis: diagnosis and treatment. *Int J Pediatr Otorhinolaryngol* 2003;67(6):635–9. [https://doi.org/10.1016/S0165-5876\(03\)00018-1](https://doi.org/10.1016/S0165-5876(03)00018-1).
- [23] De Graaff JC, Bijker JB, Kappen TH, Van Wolfswinkel L, Zuithoff NPA, Kalkman CJ. Incidence of intraoperative hypoxemia in children in relation to age. *Anesth Analg* 2013;117(1):169–75. <https://doi.org/10.1213/ANE.0b013e31829332b5>.
- [24] Merea VS, Lee AHY, Peron DL, Waldman EH, Grunstein E. CPAS: surgical approach with combined sublabial bone resection and inferior turbinate reduction without stents. *Laryngoscope* 2015;125(6):1460–4. <https://doi.org/10.1002/lary.25001>.
- [25] Sitapara JB, Mahida JB, McEvoy TP, et al. Using the maxillary-nasal angle to evaluate congenital nasal pyriform aperture stenosis. *JAMA Otolaryngol - Head Neck Surg* 2015;141(6):539–42. <https://doi.org/10.1001/jamaoto.2015.0639>.
- [26] Walsh BK, Smallwood CD. Pediatric oxygen therapy: a review and update. *Respir Care* 2017;62(6):645–61. <https://doi.org/10.4187/respcare.05245>.
- [27] Blackmore K, Wynne DM. A case of solitary median maxillary central incisor (SMMCI) syndrome with bilateral pyriform aperture stenosis and choanal atresia. *Int J Pediatr Otorhinolaryngol* 2010;74(8):967–9. <https://doi.org/10.1016/j.ijporl.2010.05.018>.
- [28] Visvanathan V, Clement AW, Wynne D. Surgical management of congenital nasal pyriform aperture stenosis. *ENT Audiol News* 2014;23(2):3–4.
- [29] Visvanathan V, Wynne DM. Congenital nasal pyriform aperture stenosis: a report of 10 cases and literature review. *Int J Pediatr Otorhinolaryngol* 2012;76(1):28–30. <https://doi.org/10.1016/j.ijporl.2011.09.016>.